

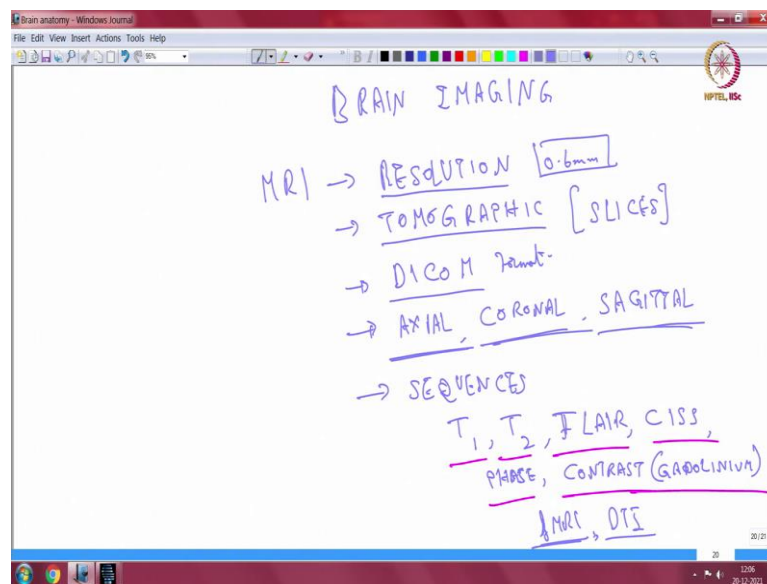
**Neural Science for Engineers**  
**Prof. Vikas V**  
**National Institute of Mental Health and Neurosciences (NIMHANS)**  
**Indian Institute of Science, Bengaluru**

**Lecture - 23**  
**Brain anatomy using MR images - I**

Hi, we are back again and in the previous session I did a brief course on brain imaging, various modalities, the principles, everything crammed into one. I feel that is sufficient for the audience, people who are interested are definitely welcome. It's a very interesting field of study. And the reason I had to delve into it is because what we are going to discuss now is the output of the whole story.

And so, you need to know how the input is to, actually figure out how to interpret the output. So, that was the point. Now we will start with the brief revision of some keywords.

(Refer Slide Time: 01:04)



So, brain imaging what I am going to discuss is going to be MR images because of its high resolution and popularity with students and for various kinds of research projects. So, that is one reason why I am doing. You have to understand that these are tomographic, basically indicating that, slices of tissues are interrogated. So, these are MR images available in something called as DICOM format.

So, these are the keywords which you need to understand. So, slice-based imaging also indicates that you should know what is axial, coronal, sagittal imaging. So, these are terminologies which you should be familiar with. So, when we spoke about resolution, we spoke about slice thicknesses of resolutions, overall resolutions of 0.6 mm resolution between two structures. It is nowhere what as surgeons we require and as many people who do diagnostic imaging require, but it's the available resolution.

So, tomography is you are interrogating tissue in slices. So, when I did my anatomical description, I made it a point to show you stuff in 3D and in best fashion which I could think of. But whenever you are looking at any kind of imaging you are always looking at slices, there are very few places where you actually look at 3D, that is because actually of the way in which the imaging has developed.

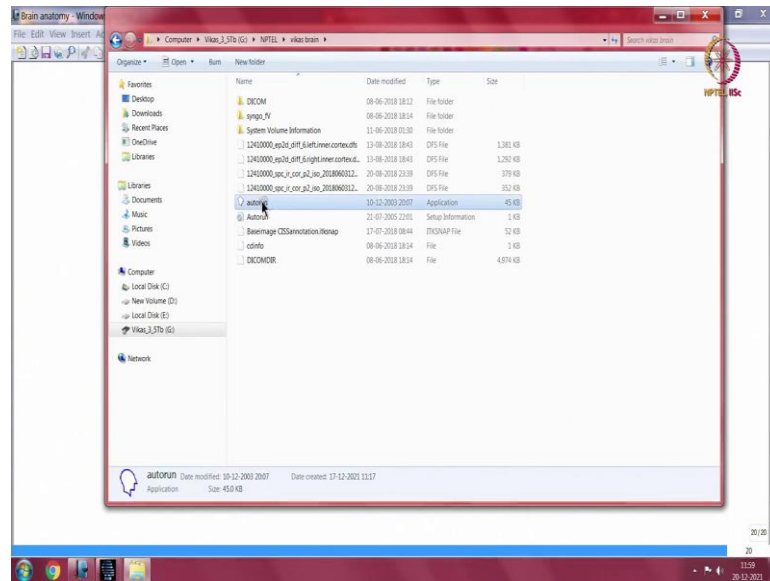
Say for example, we as surgeons we would prefer to see everything in 3D rather than 2D because it takes some effort on our side to interpret a 3D image which you see on CT and MR images and films and stuff and then assimilate the 3D knowledge out of it. But anyway, that is how it is and you cannot change things. DICOM is important because that is the mode of communication, it's the standardized format in which the images are given to you in slices.

And then you have a DICOM viewer which is necessary for viewing the images. DICOM images usually are given along with the CD, pen drive, etcetera and then you need to open there are several open source DICOM viewers which are available online through which you can view the imaging.

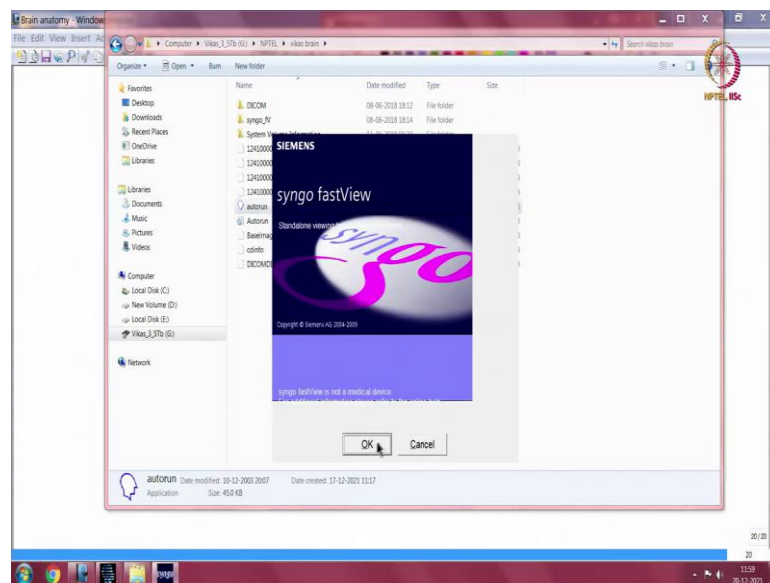
So, that is about it and then you need to understand these terminologies. What is axial images, coronal images and sagittal images? So, axial is like this ok. So, it's a slice. So, your entire head is in slice and that is the axial images. Coronal is parallel to your face so as to say. Sagittal is like this.

So, coronal, axial and sagittal. So, that is the terminology. No need to mug up this. I will be showing it to you, but I needed you to be comfortable with the terms rather than what actually they mean. So, that is the idea.

(Refer Slide Time: 04:55)

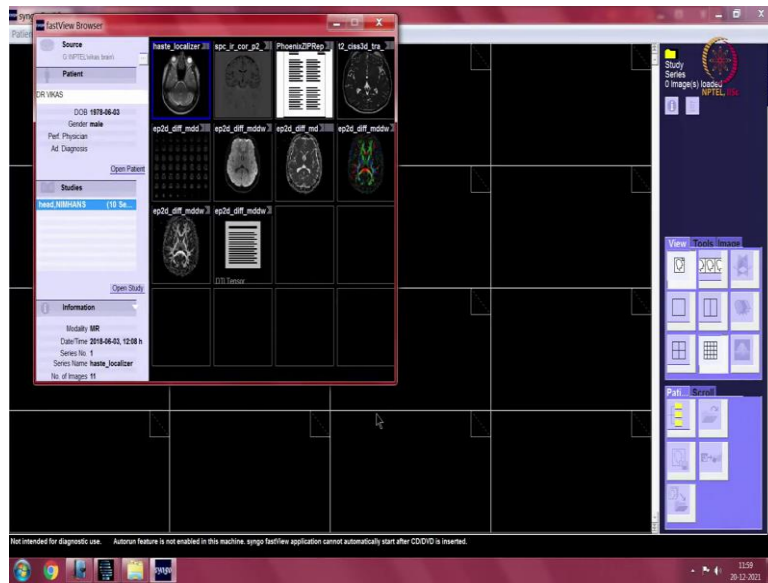


(Refer Slide Time: 04:58)

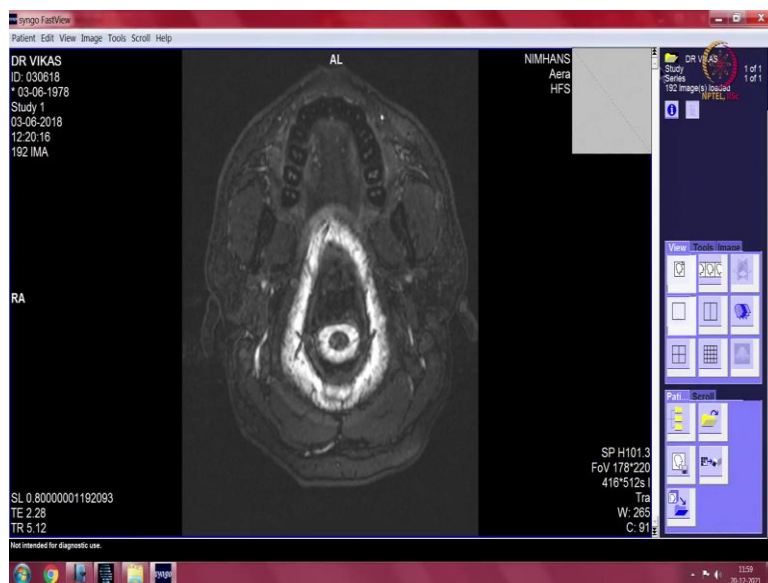


Now, if you look at imaging this one you would find there is an app which runs the DICOM viewer.

(Refer Slide Time: 05:00)



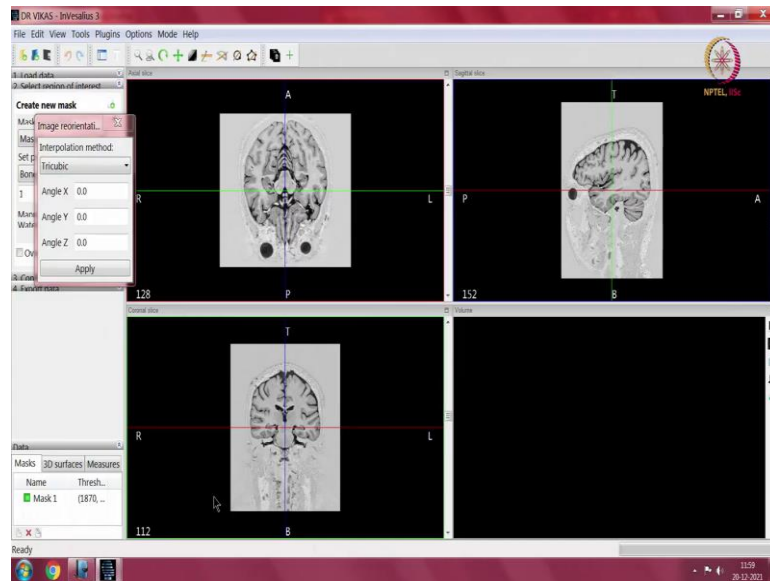
(Refer Slide Time: 05:04)



And then you can basically you can basically scroll through some kind of imaging which is available. So, that is how these things run. So, anyway I am not going to show you that part of the story. What I would want to make you see is how to interpret images.



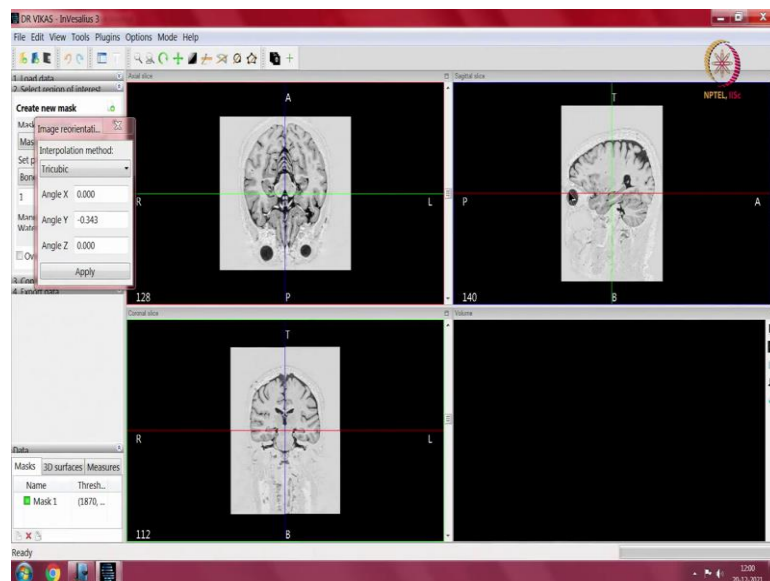(Refer Slide Time: 05:26)



And I use this particular thing for demonstrating my images. So, this is from InVesalius which is one of the packages, there are several of these packages. So, there is ITK-SNAP, SNP which is one of the most popular ones. You have osseous which is a viewer platform on apple, and my personal favorite is InVesalius for the kind of research stuff which we do for some specific purposes.

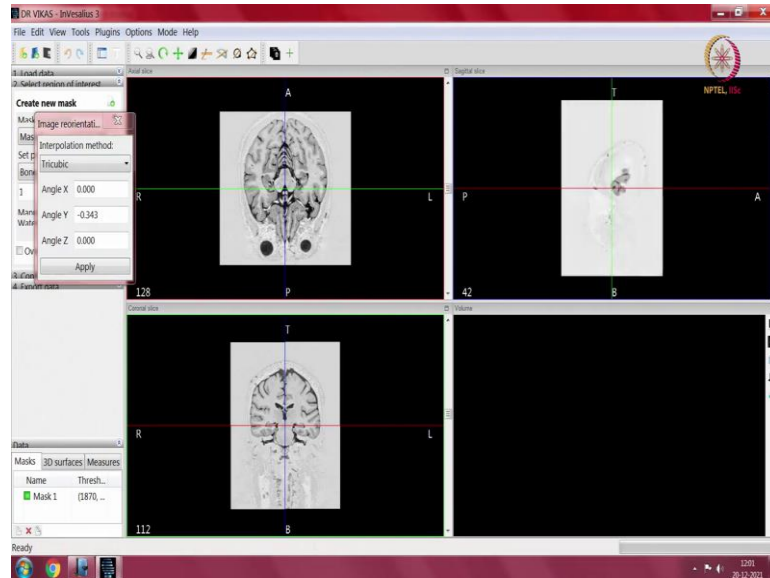So, I am using InVesalius because I am comfortable with it. So, this is a coronal image I can draw. So, this is what I mean by a sagittal image.

(Refer Slide Time: 06:24)



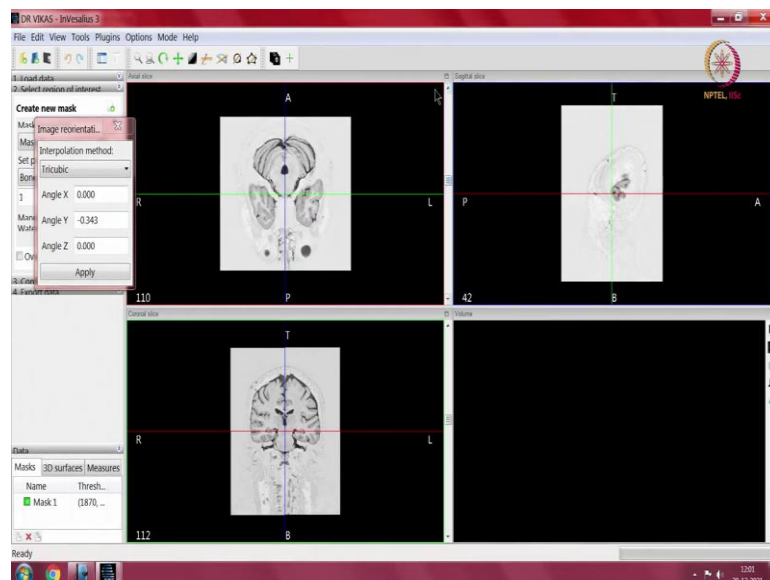
The eye in front, this is the back of the head, upper part superior inferior. So, this is a sagittal image.

(Refer Slide Time: 06:42)



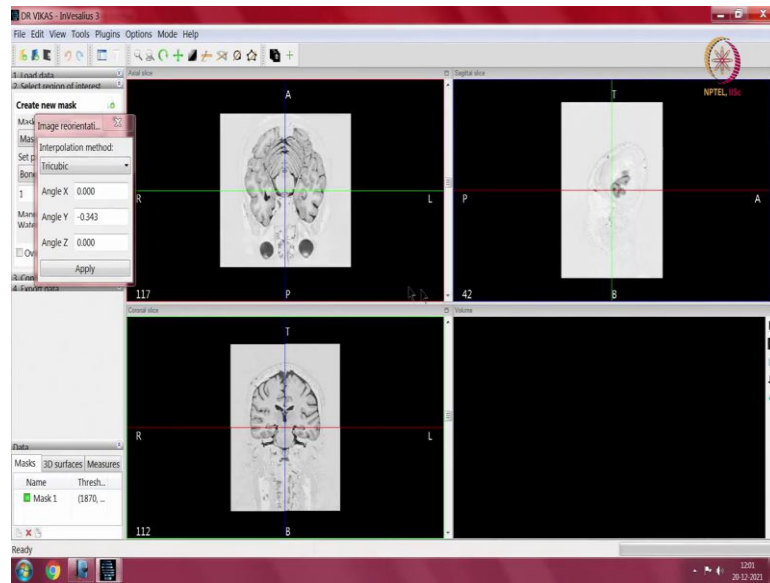
So, that is how a sagittal image looks like. This is an axial image, it is upside down I will be sorting it out in the description part of the story.

(Refer Slide Time: 06:51)



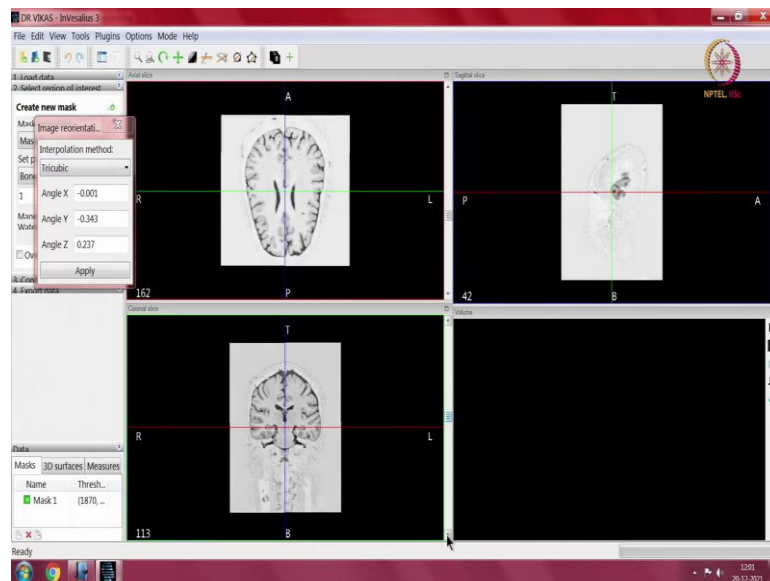
But do recollect. So, this is how the eye is on one side.

(Refer Slide Time: 06:56)



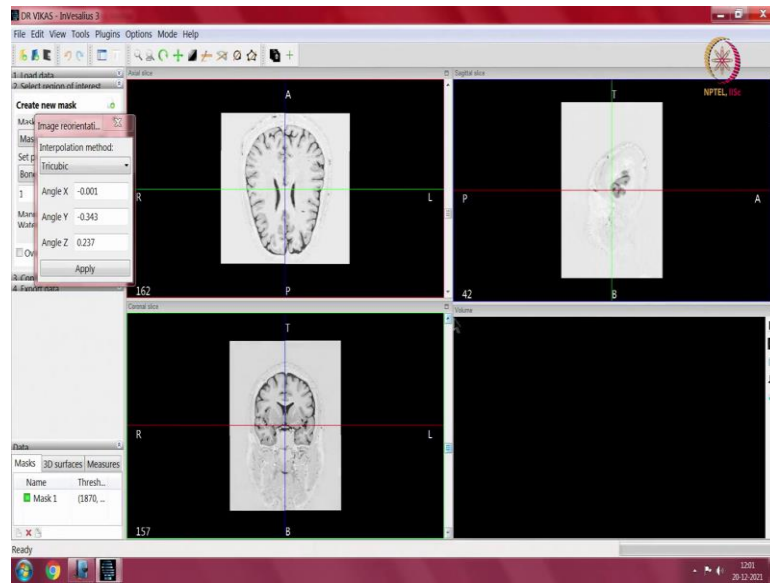
This is the eyes, two sides eye and the back of the head.

(Refer Slide Time: 07:06)



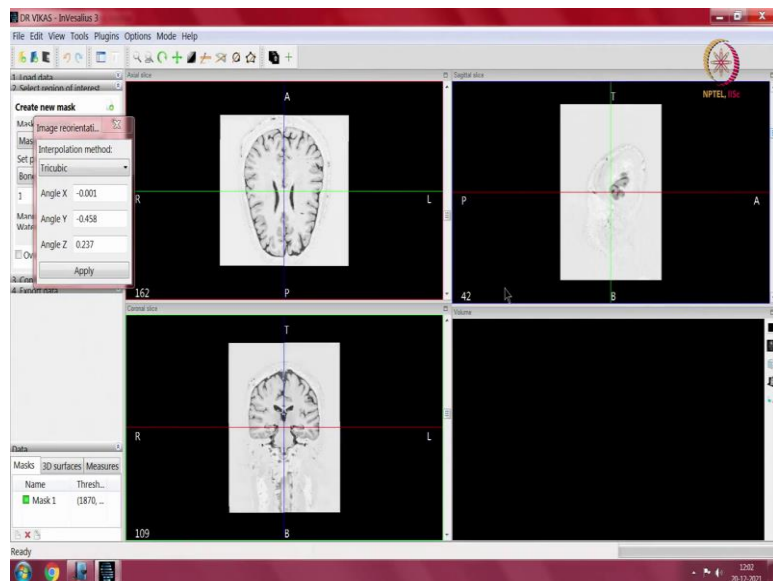
This is coronal section.

(Refer Slide Time: 07:12)

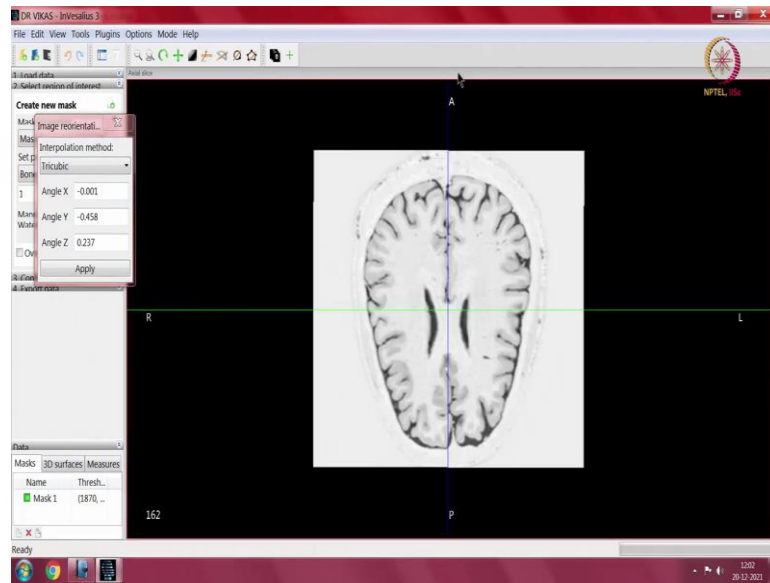


What do you, what you can make out is the ears.

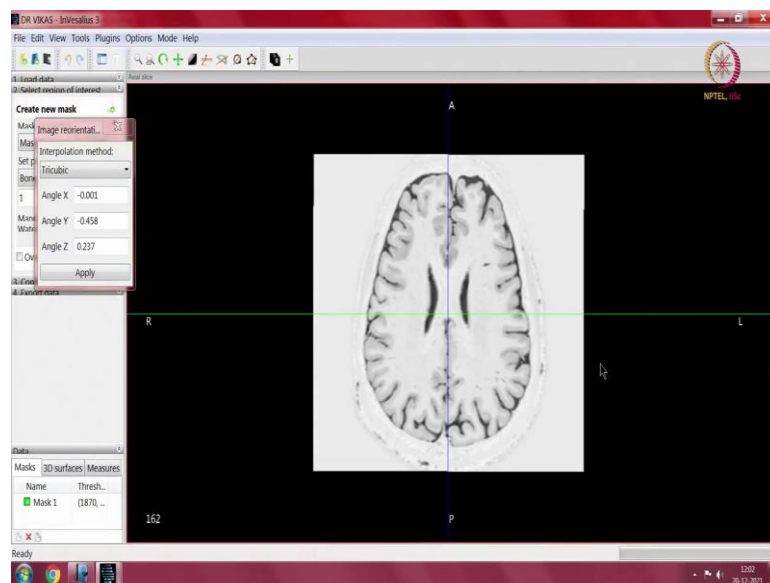
(Refer Slide Time: 07:16)



(Refer Slide Time: 07:22)

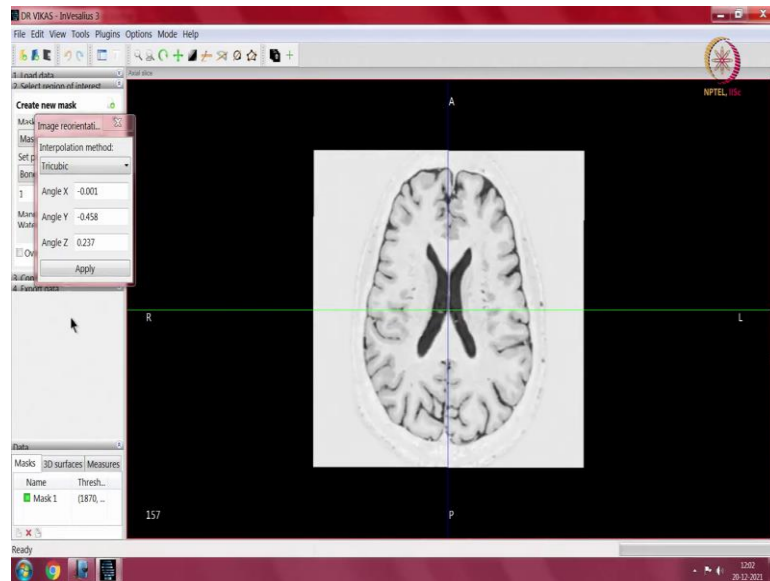


(Refer Slide Time: 07:24)



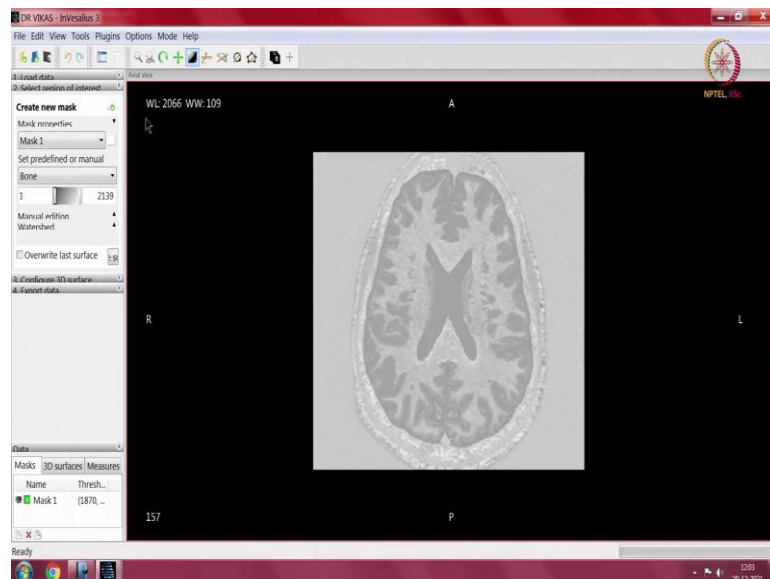
So, we will start our run of anatomy through the axial images.

(Refer Slide Time: 07:27)



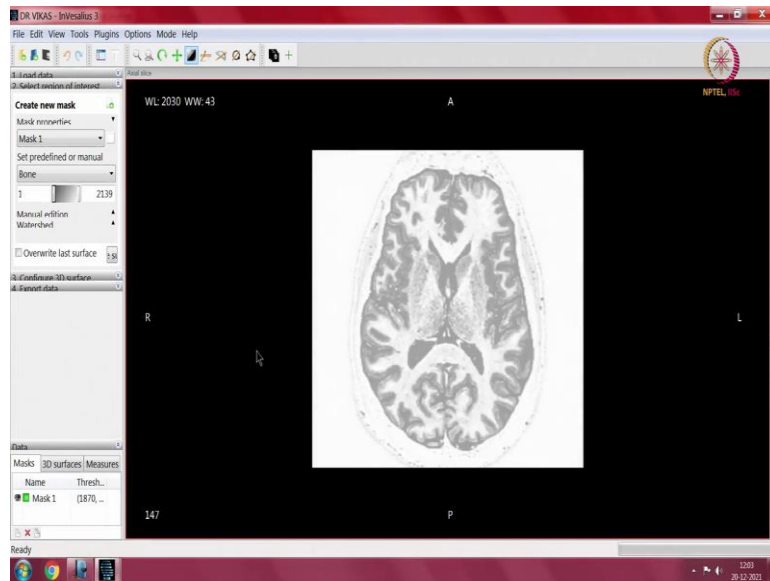
So, this is how the image looks like we will.

(Refer Slide Time: 07:30)



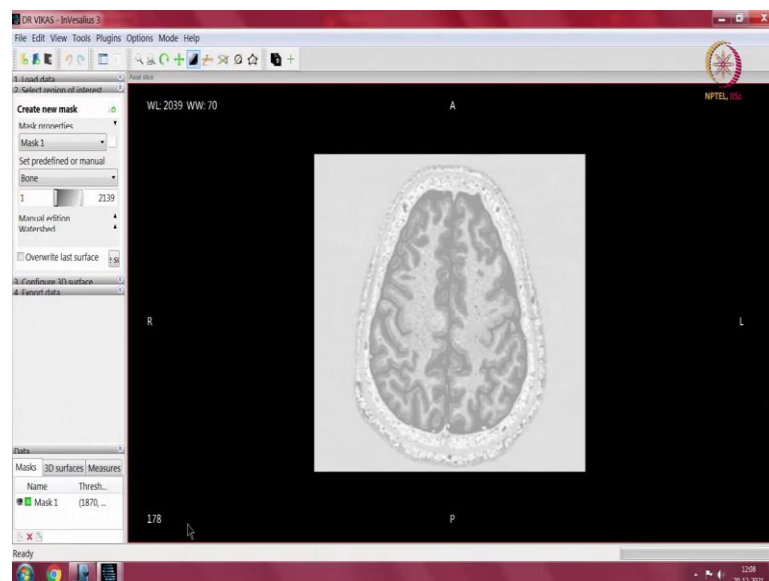
So, there is something called windowing. So, windowing helps in making things. Windowing is a method of changing, its a concept which is basically borrowed from CT and what windowing does is, it helps you to improve the contrast and there are two things windowing width and this is the larger window which you can change.

(Refer Slide Time: 08:02)



Looking at an optimal place where you can see.

(Refer Slide Time: 08:11)



So, now, I have not spoken to you about MR sequences; MR sequences is something which I have to speak about. Now I spoke to you about how hydrogen you give the magnetic field and then you give a radio frequency pulses. So, combinations of these parameters, radio frequency parameters, the magnetization parameters are given as user controls.

And that is how you have various sequences such as T 1, T 2 then you have FLAIR, then there is CISS image, then phase then contrast is you give by injection some material into the blood which is gadolinium. And that shows up. Its relevant for especially structural lesions such as tumors in which the tumor takes up the gadolinium and helps in contrast differentiation from surrounding brain which does not take gadolinium.

So, there are several other kinds of sequences, but what you would need to remember these set of things. So, sequences determine the way in which you interpret brain images. Each sequence has its medical relevance, there are certain things which are better seen on a particular sequence and that is the point.

But if you remember I had used the analogy of car gears for that purpose, because they are fixed you know you have only those parameters which can tune and even people who are doing image processing have to remember what sequence is being used. Because you use an inappropriate sequence you do not get the relevant output which you want.

So, please be careful in choosing sequences and choosing sequences for your study for your analysis for your data whatever. So, they are they all the sequences image the brain. But they look at different issues in the brain. So, I have not included FMRI, then diffusion tensor imaging. These are more advanced techniques as I told you each has its relevance FMRI for example, its functional.

So, it tells you something about the functional activity which is there in a particular part of the; part of the brain based on oxygen consumption. And it is unfortunately of low resolution. So, it the functional MRI is superimposed upon normal MRI, functional MRI itself is a derivative of statistical analysis of very fast acquisitions.

So, you have multitudes of images taken in a short period of time, then you statistically average to get the output. So, there is a lot of statistical algorithms which are there which get you the FMRI images and the FMRI images in turn are superimposed on T1 sequence images. So, please do look back into that.

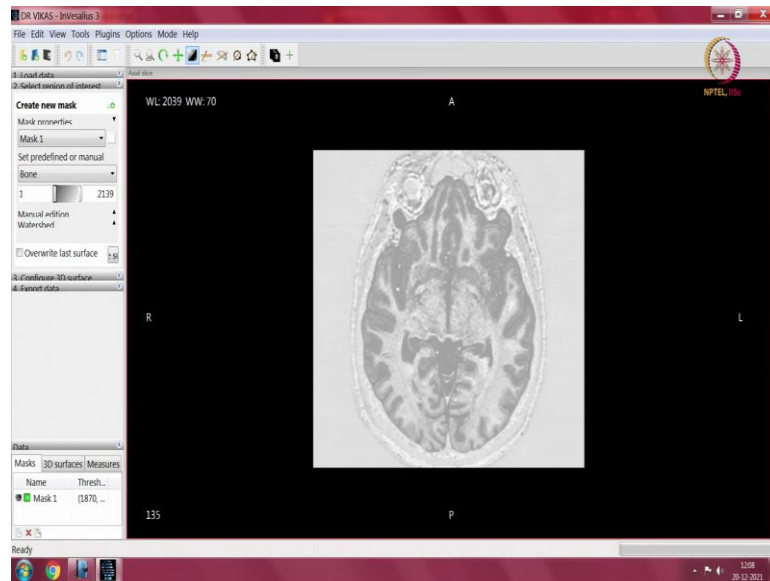
So, if somebody is starting with saying yeah I am going to study FMRI images and that is the output image which you are seeing with all the colors and stuff like that, please remember that there are two base imaging sequences in play, the acquisition parameters



of both the imaging sequences are completely different, the purpose of the acquisition is different, the slice thickness is different, everything is different.

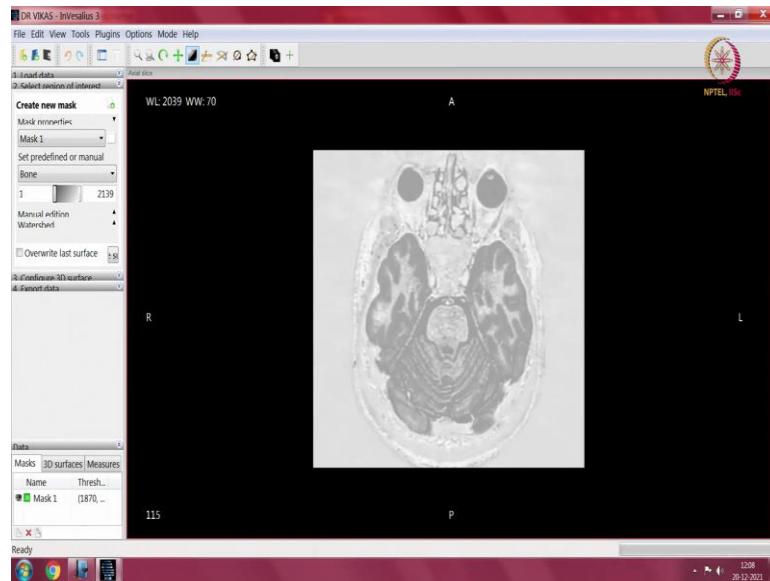
So, what we as clinicians see and what you would do in image processing should be completely different. Please do not use the same perspective which we have for processing these, images that is the point. So, we will come back to our topic, I am not teaching MR imaging over here I am teaching anatomy over here.

(Refer Slide Time: 12:20)



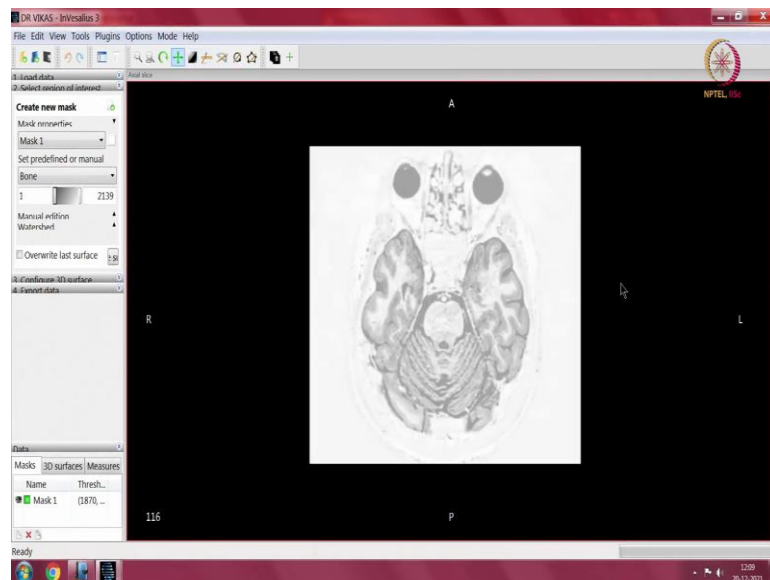
So, we will start with some basic notions which. So, this is a T 1 sequence it is actually not a completely T 1, it's called a highly weighted T 1 with a specific purpose.

(Refer Slide Time: 12:35)



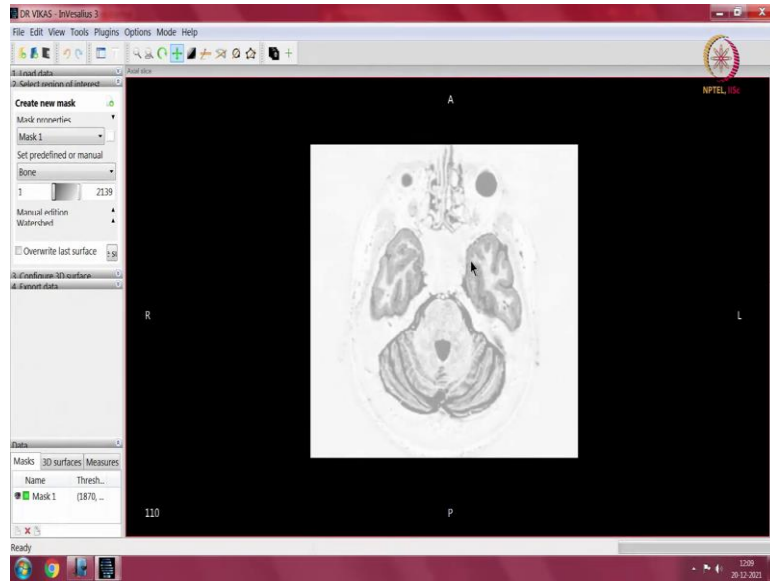
It is a designed so as to give you idea of gray and white matter tissue ok. So, that is the idea of this sequence.

(Refer Slide Time: 12:44)



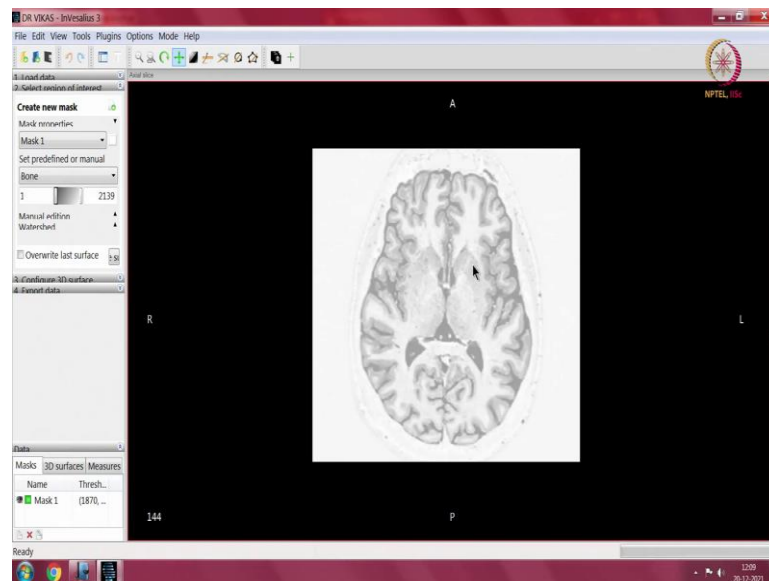
What is obvious here? We will start with the obvious and then go to other things which are not so obvious. So, this is the eye over here. So, please remember this is left, this is right, anterior and this is posterior. So, that is the nomenclature which is there. So, anterior is eye and sectional indicates that it's a section. So, section is the eye is the most prominent part. So, between the two eyes is the nose, that is the nose area.

(Refer Slide Time: 13:21)



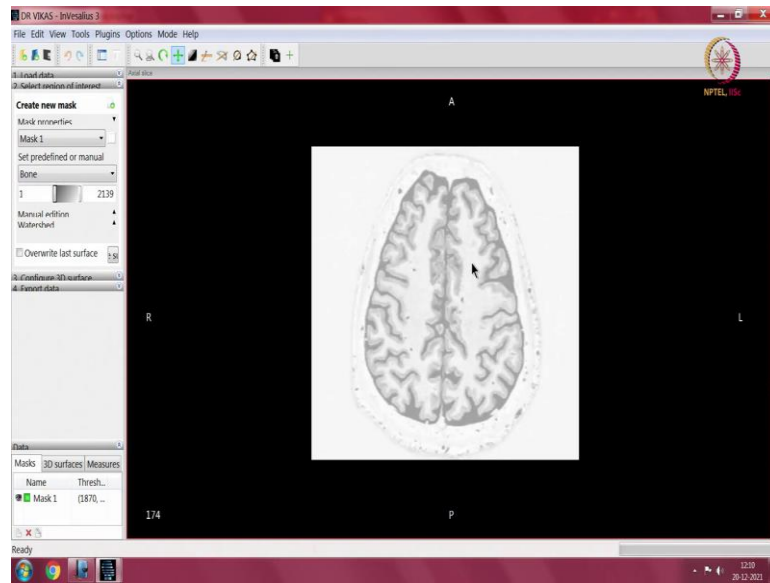
So, that is to give you a context of how things are being described.

(Refer Slide Time: 13:28)



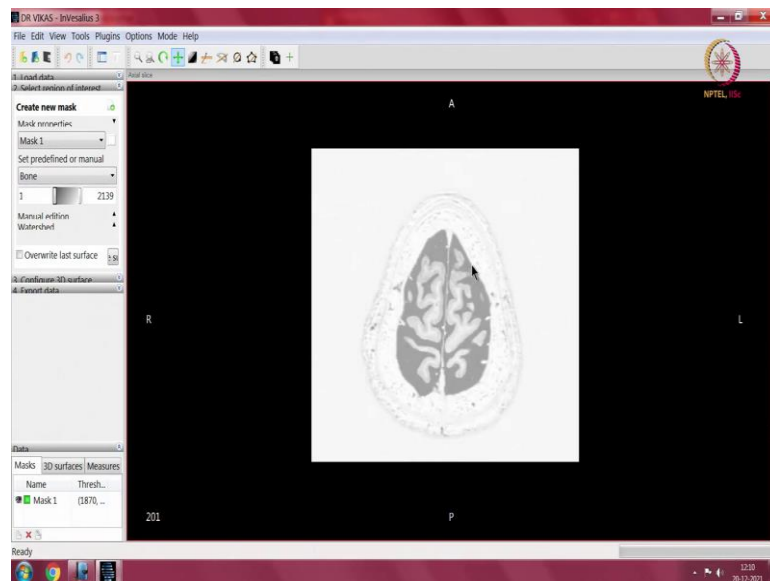
So, scrolling up as in towards the scalp and above the eye.

(Refer Slide Time: 13:36)



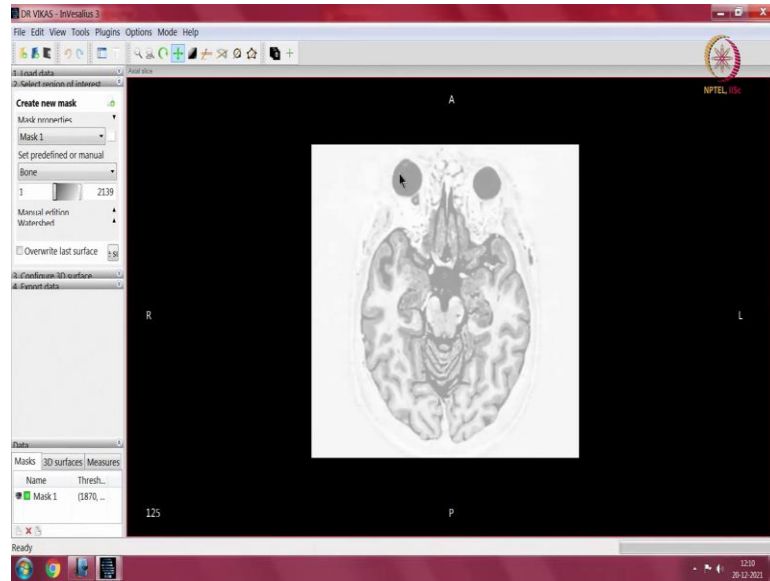
So, there is no eye seen over here.

(Refer Slide Time: 13:39)



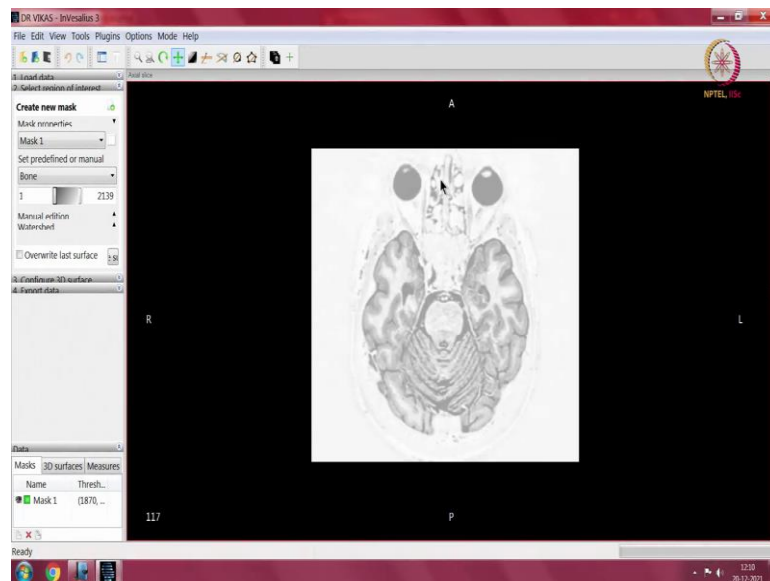
So, that is how we scroll above, this is an axial slice remember again. Now we have reversed moment going down to see the eyes back again here.

(Refer Slide Time: 13:56)



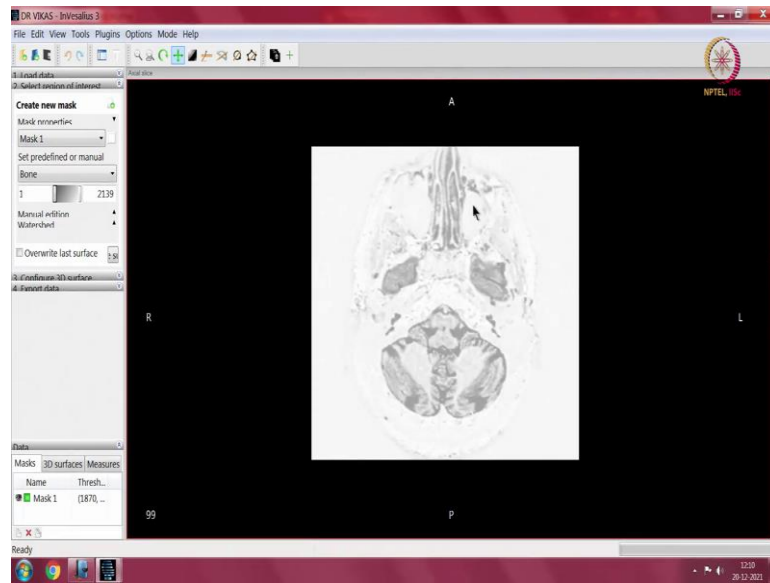
These are the two eyes again.

(Refer Slide Time: 13:59)



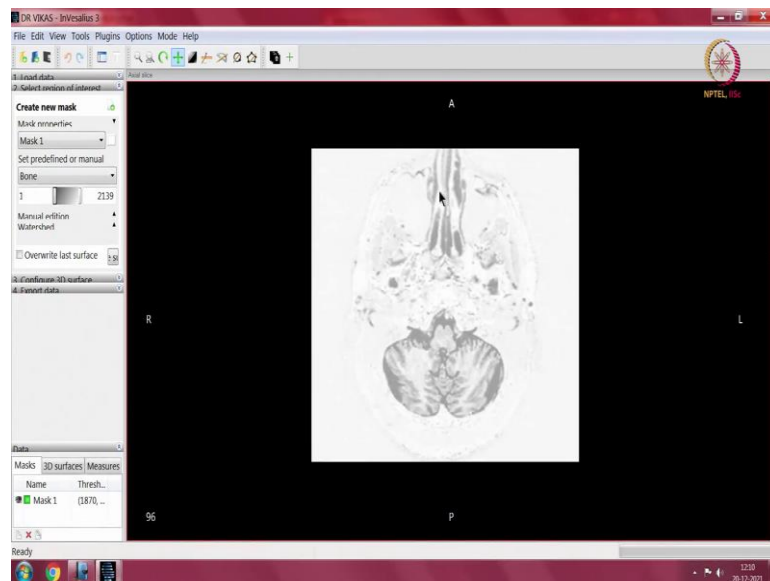
We continue down to see the nose.

(Refer Slide Time: 14:03)



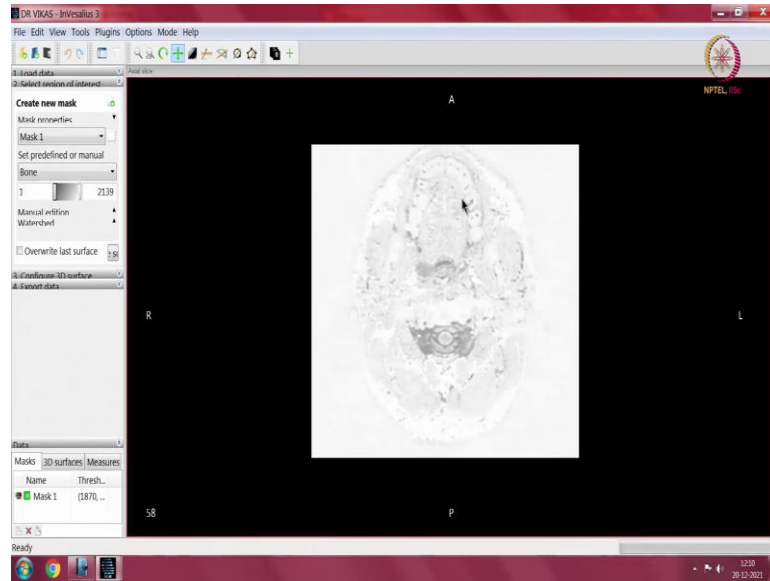
This is the Paranasal sinuses on either side.

(Refer Slide Time: 14:07)



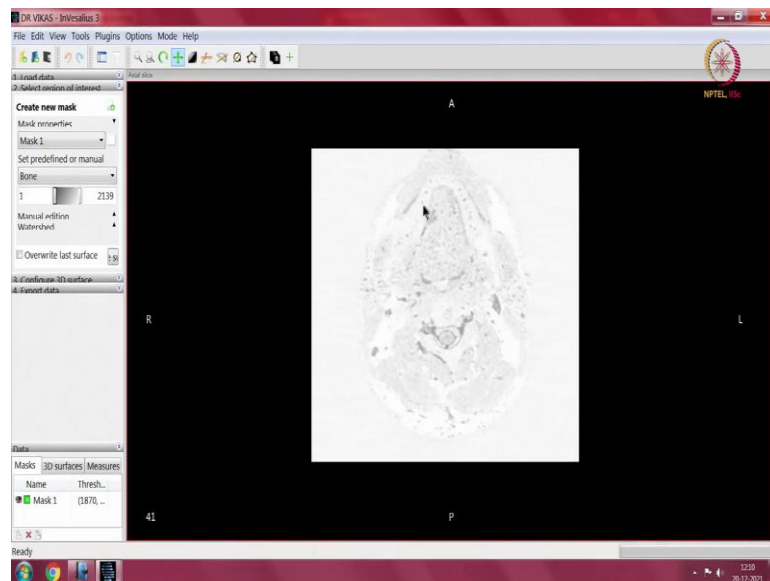
This is the nose again still.

(Refer Slide Time: 14:14)



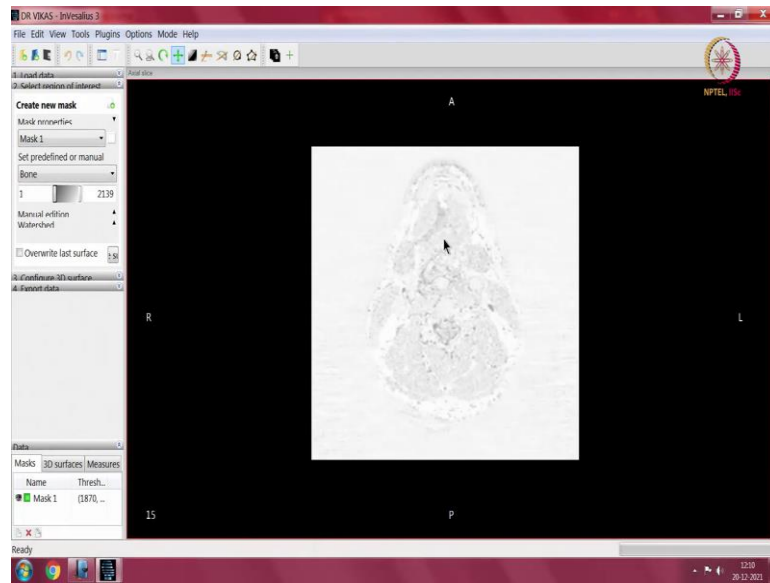
This is the teeth ok.

(Refer Slide Time: 14:21)



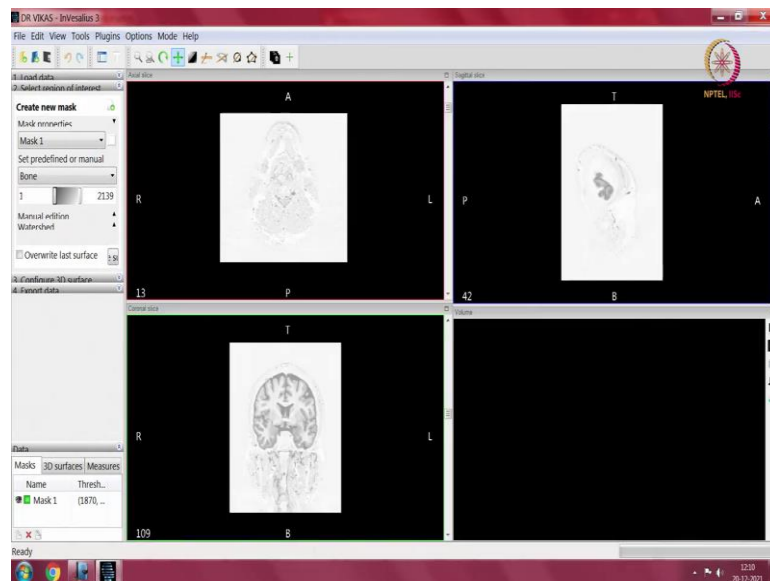
So, teeth jaw teeth lower meaning the lower part of the teeth.

(Refer Slide Time: 14:27)



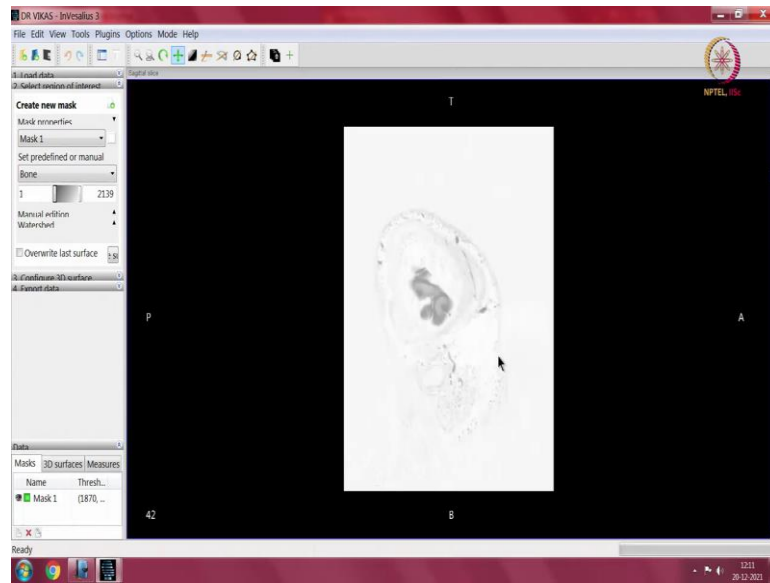
And, so that is the lowest most part of the structure.

(Refer Slide Time: 14:34)



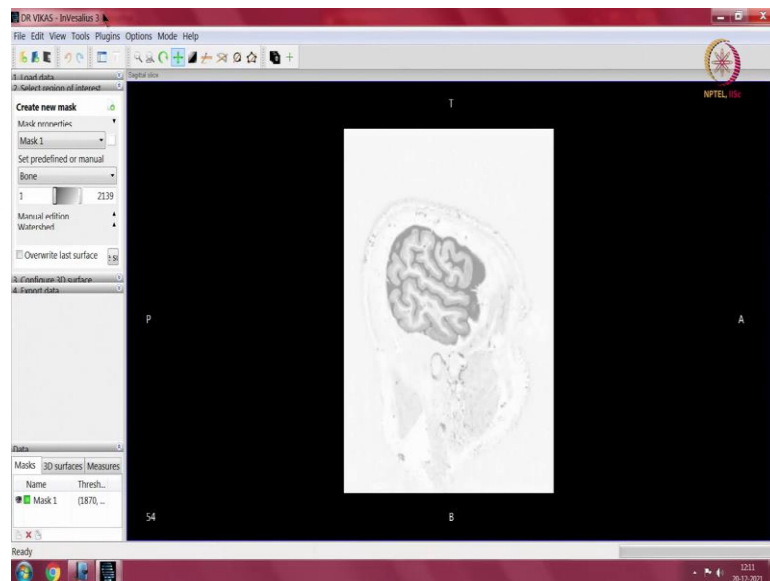


(Refer Slide Time: 14:38)



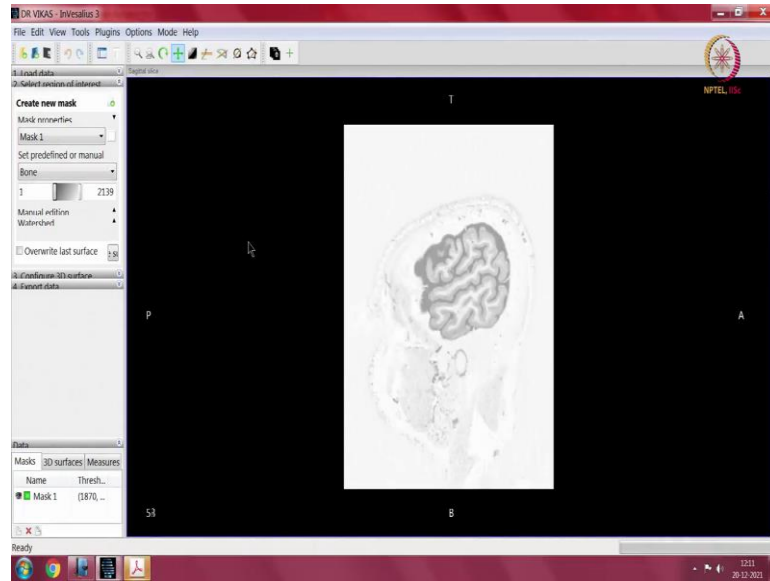
So, we look at other parts of the anatomy.

(Refer Slide Time: 14:40)



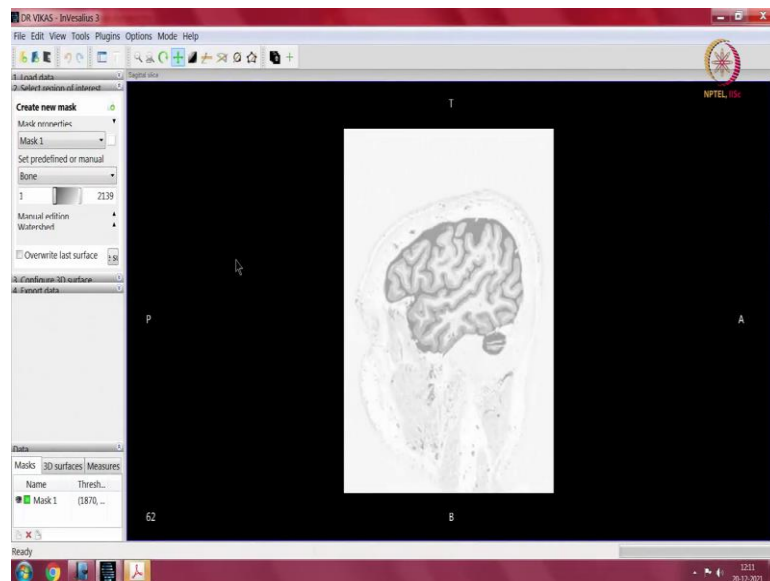
Anterior posterior generally we would see it like this flip.

(Refer Slide Time: 14:47)

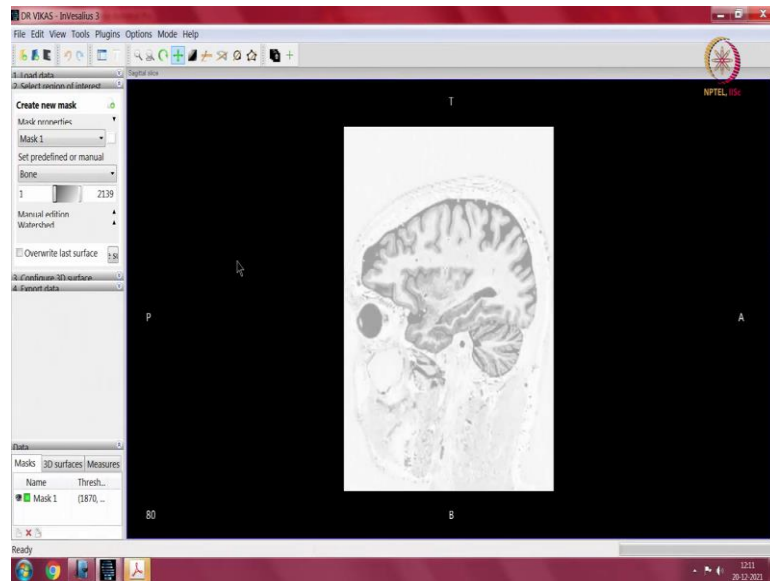


So, anterior, posterior this is sagittal section.

(Refer Slide Time: 14:49)

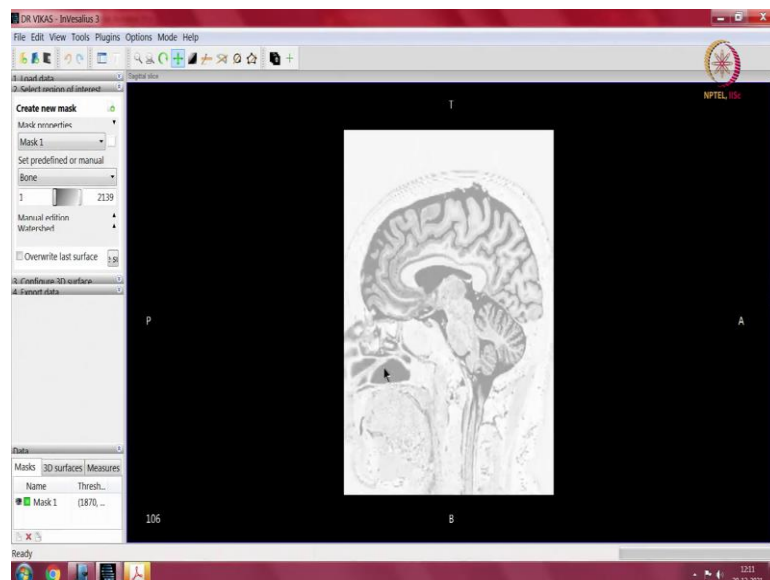


(Refer Slide Time: 14:52)



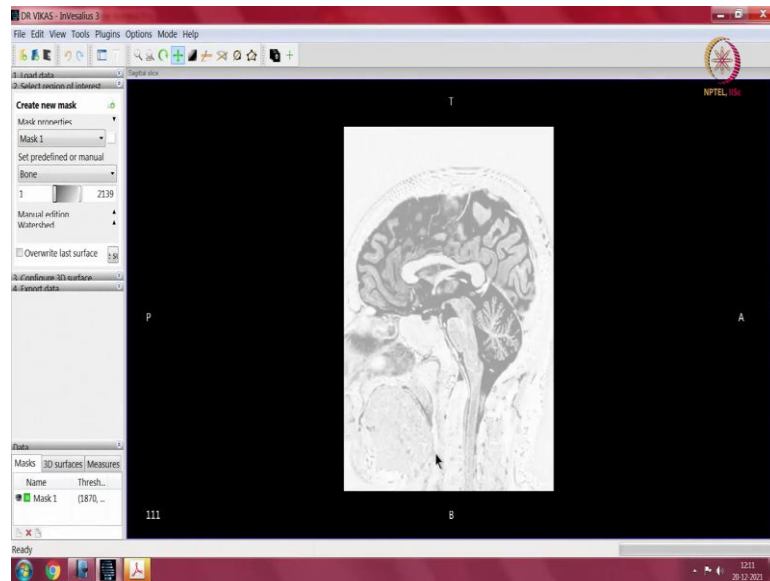
So, sagittal section is vertical cross. So, this is an eye again please do not look at the nomenclature here. I have done a flip. So, this is the eye. Then this is the back of the head, upper part of the head, lower part of the head.

(Refer Slide Time: 15:16)



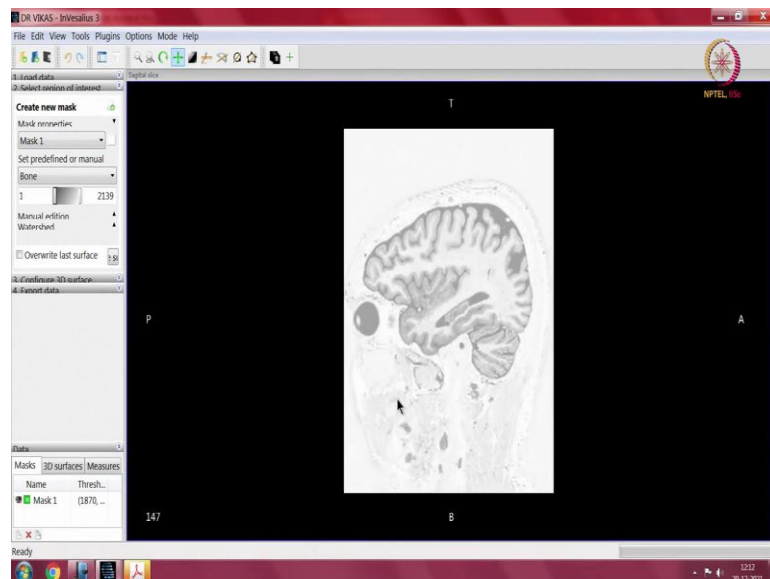
Coming towards the midline you can make out the nose here.

(Refer Slide Time: 15:22)



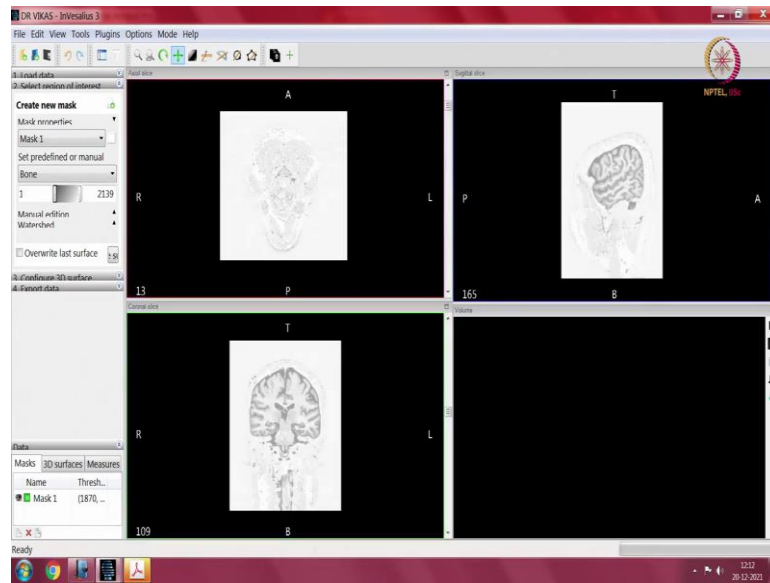
Tongue here and then the opposite side of the brain.

(Refer Slide Time: 15:28)

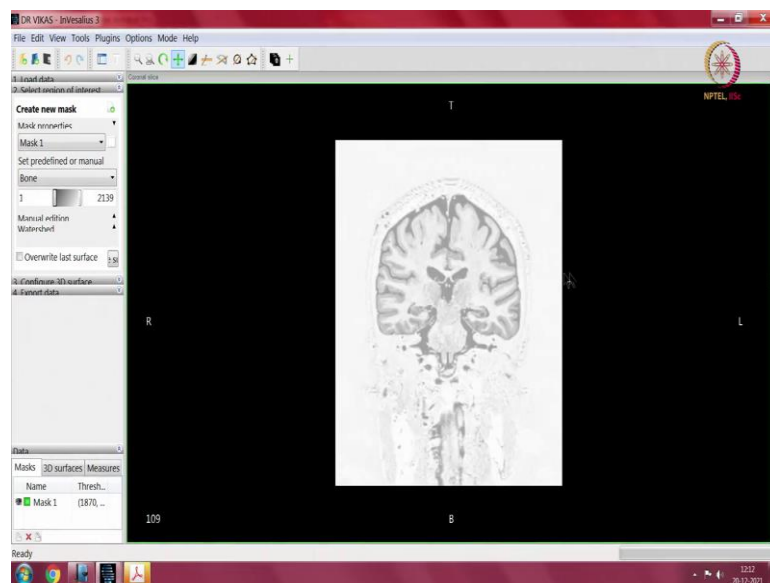


So, this is sagittal, I am repeating so you become familiar with the terminologies and what set of images are associated with that.

(Refer Slide Time: 15:34)

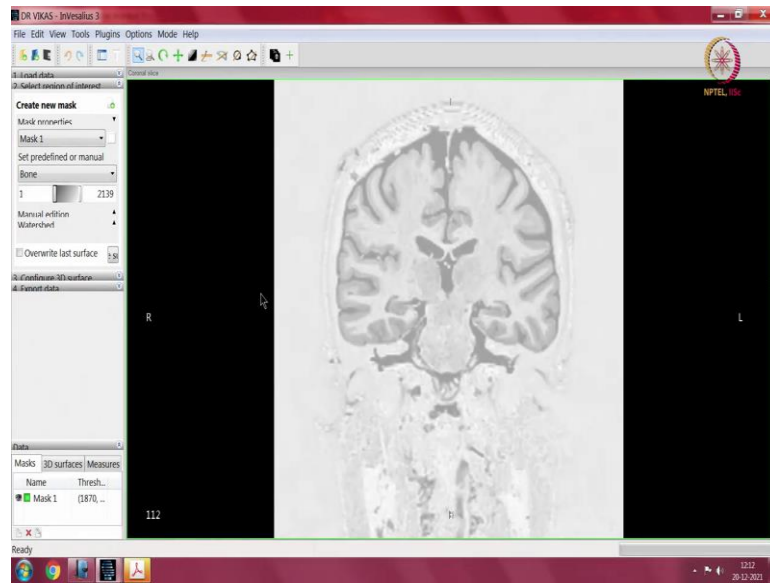


(Refer Slide Time: 15:37)



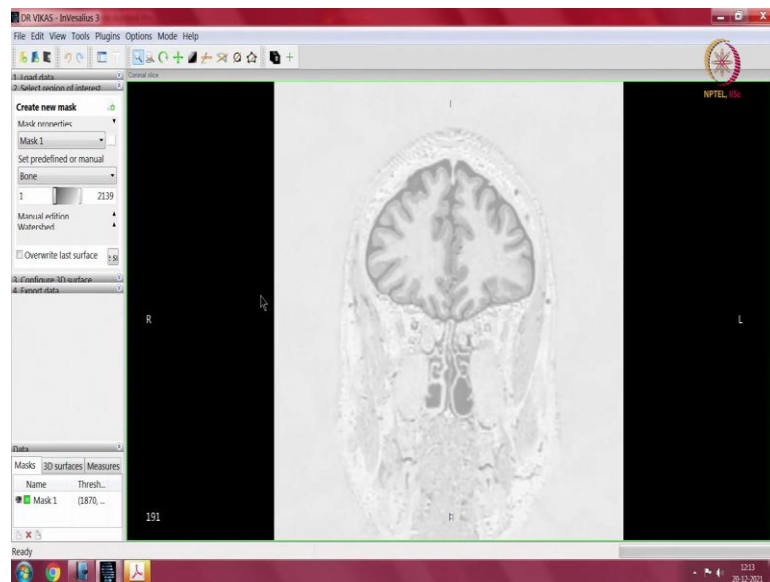
The last kind of sequence is the coronal sequence.

(Refer Slide Time: 15:52)



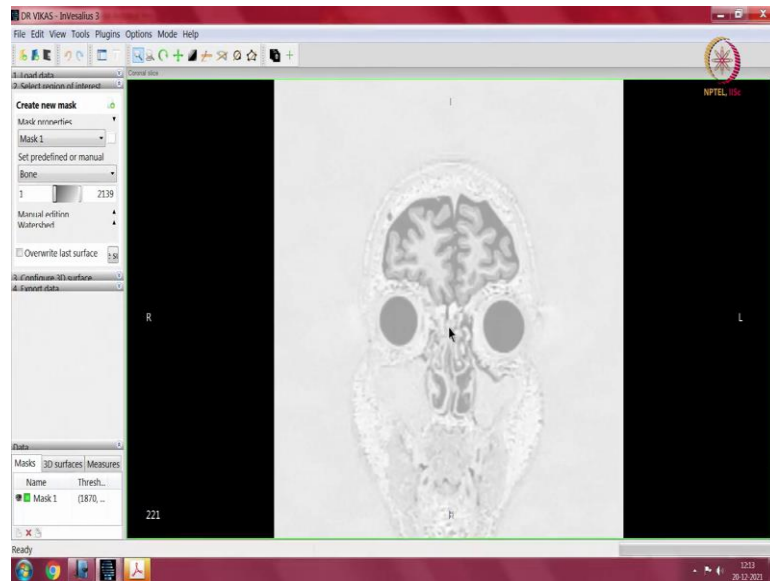
So, coronal sequence is side to side. So, how do I show side to side? I should show back the eyes and then you would get an idea. So, this is side to side cut and.

(Refer Slide Time: 16:07)



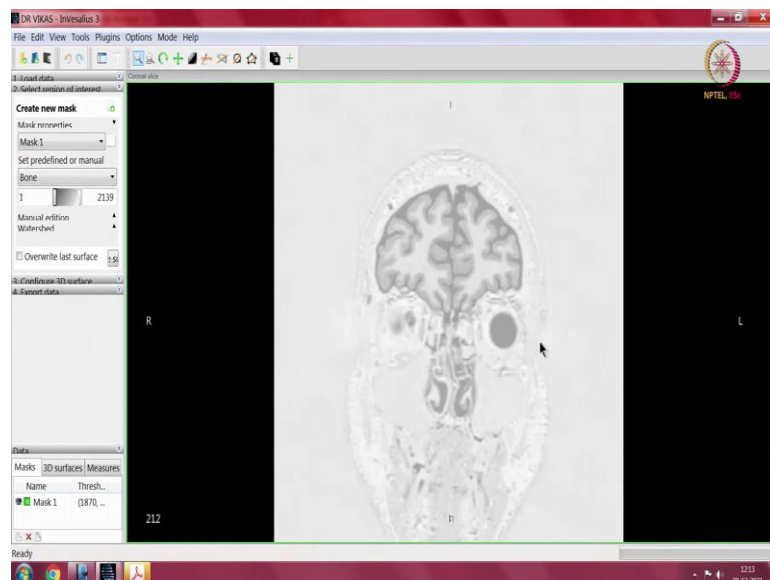
So, here comes the eyes.

(Refer Slide Time: 16:12)



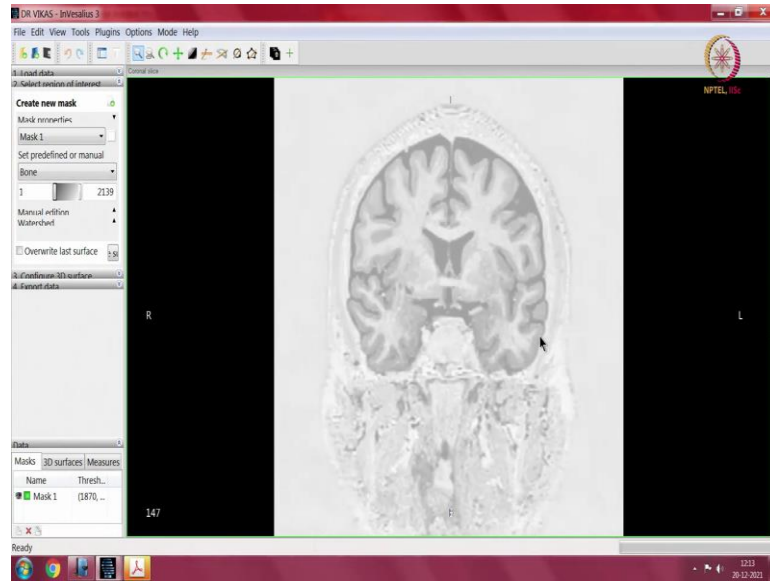
Here are the two eyes. So, this is eye and nose. And you should always interpret images as if the person is looking towards you. So, when the person is looking towards you, this is the left eye, right eye and that is how it is ok.

(Refer Slide Time: 16:31)

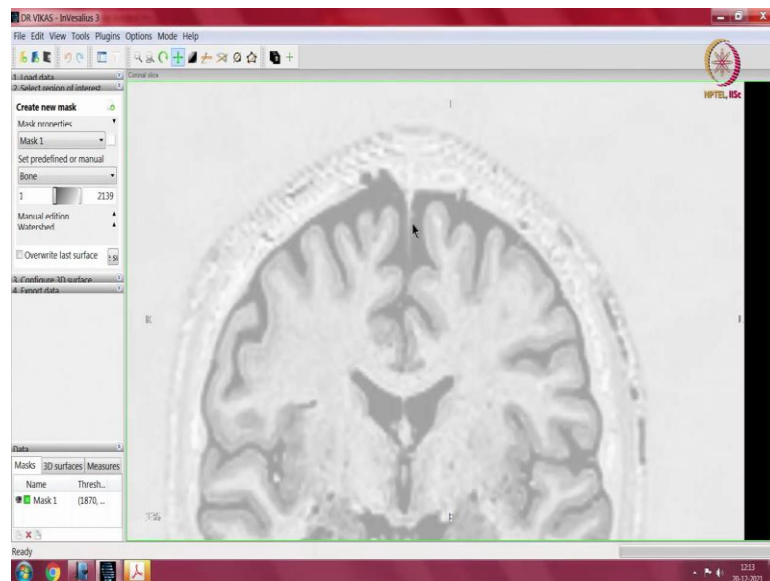


So, these are conventions, there is no hard and fast rule. In fact, you saw me flip through the image a couple of minutes back. So, that is how it is. So, now once you got a fair enough orientation of what axial, coronal and sagittal means I will start with something again which we know.

(Refer Slide Time: 16:49)



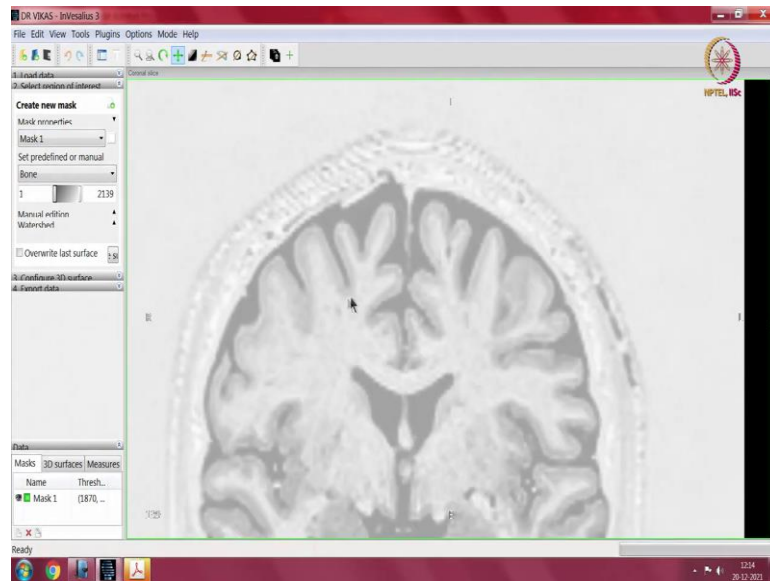
(Refer Slide Time: 16:53)



So, in my 3D demo I had spoken to you about this separation which is there between the two halves of the brain. So, here you can see the structure that is the falx ok.

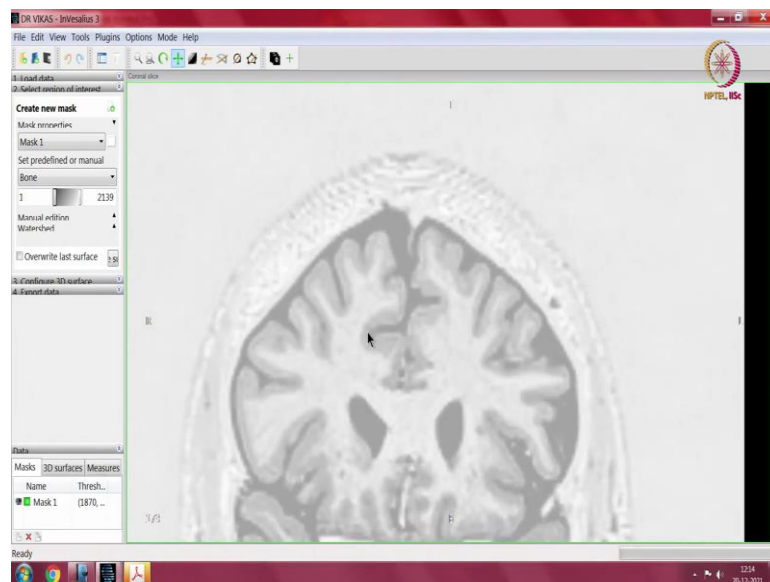


(Refer Slide Time: 17:03)

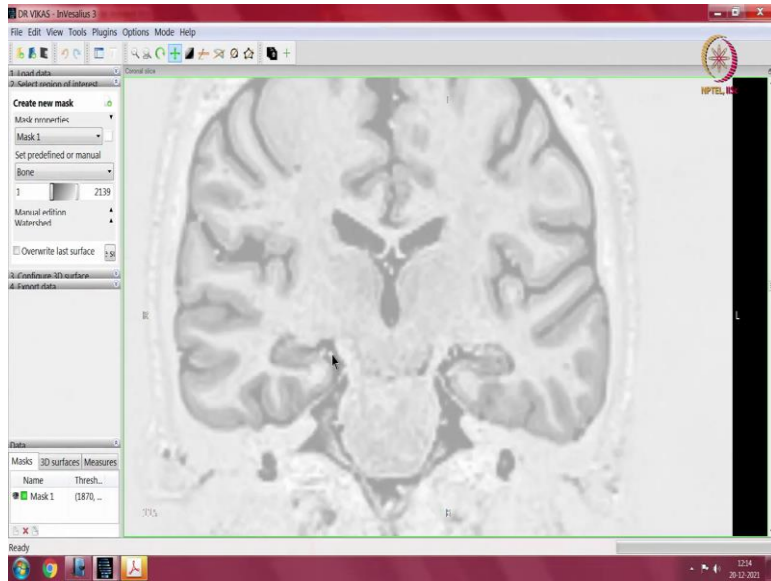


So, this is one hemisphere, this is another hemisphere. So, I told you if a person is looking towards you. So, this is the left this is the right side of the cerebrum I am using the term cerebrum because it's the upper part of the brain.

(Refer Slide Time: 17:17)

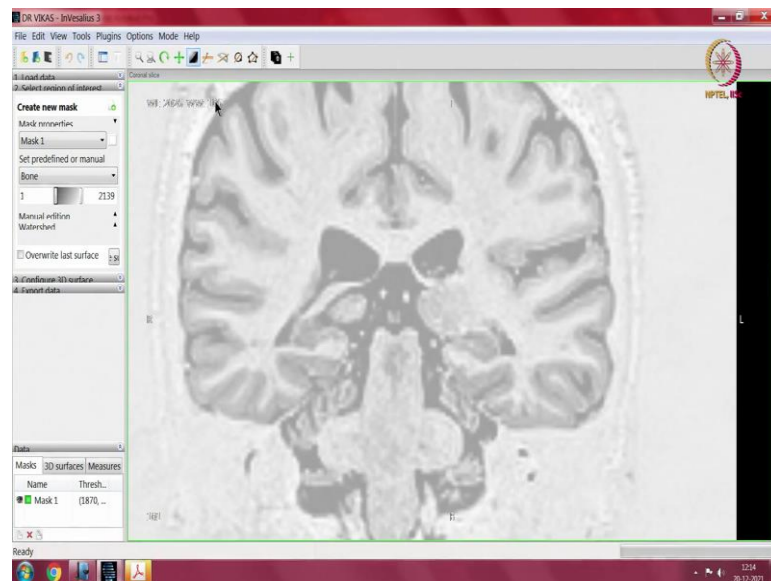


(Refer Slide Time: 17:28)



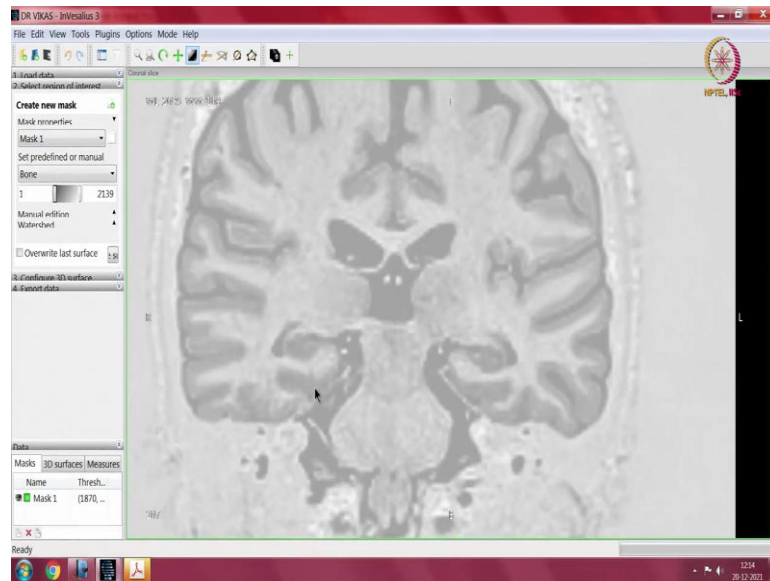
So, we go back cerebrum.

(Refer Slide Time: 17:31)



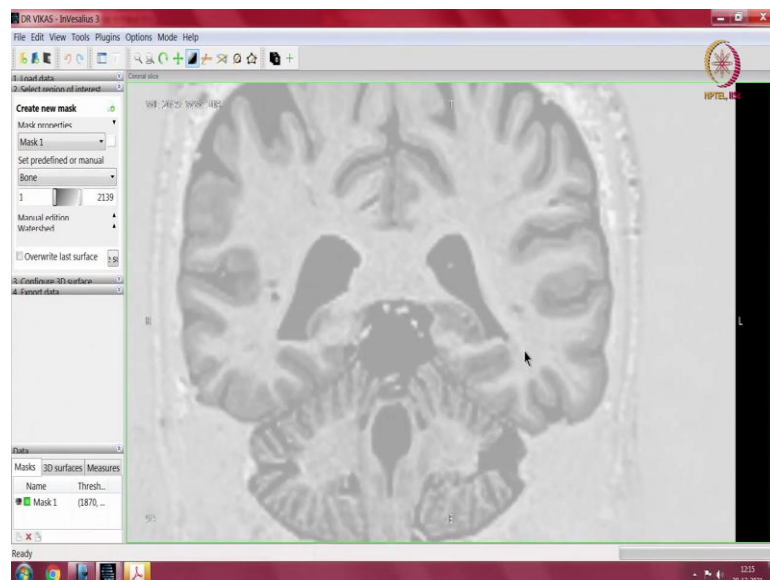
We can see the falx continuing. Then we shift down to understand this part ok.

(Refer Slide Time: 17:42)



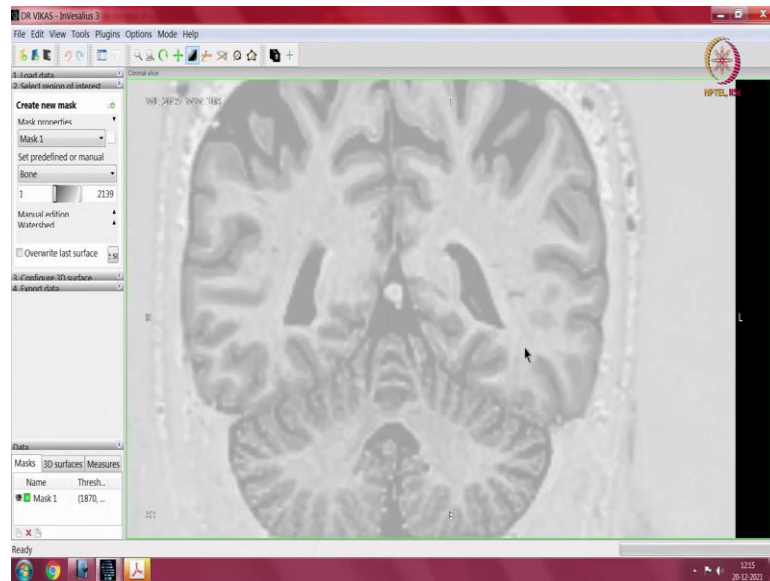
So, here you can see some structure white over here and white over here. If you remember my 3D discussion of the skull that is the tentorium. So, the tentorium divides the cranial cavity into two parts, these are the sections.

(Refer Slide Time: 17:58)



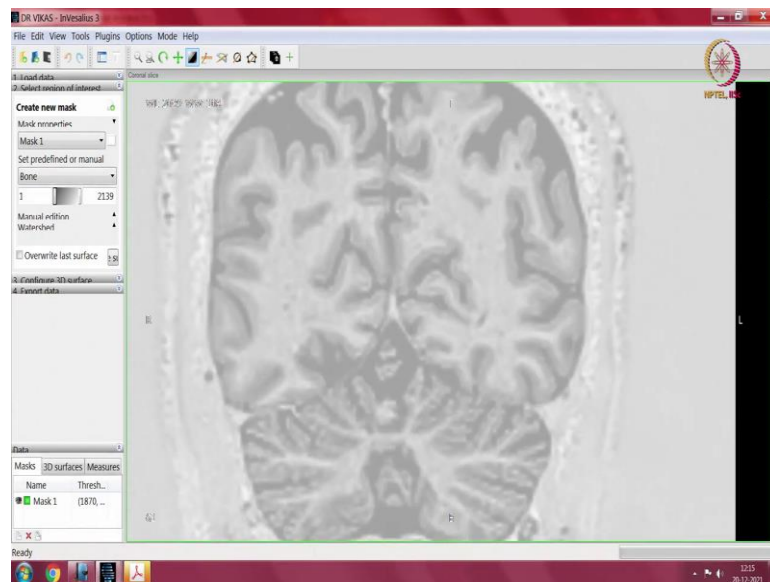
So, sections continuum sections.

(Refer Slide Time: 18:03)

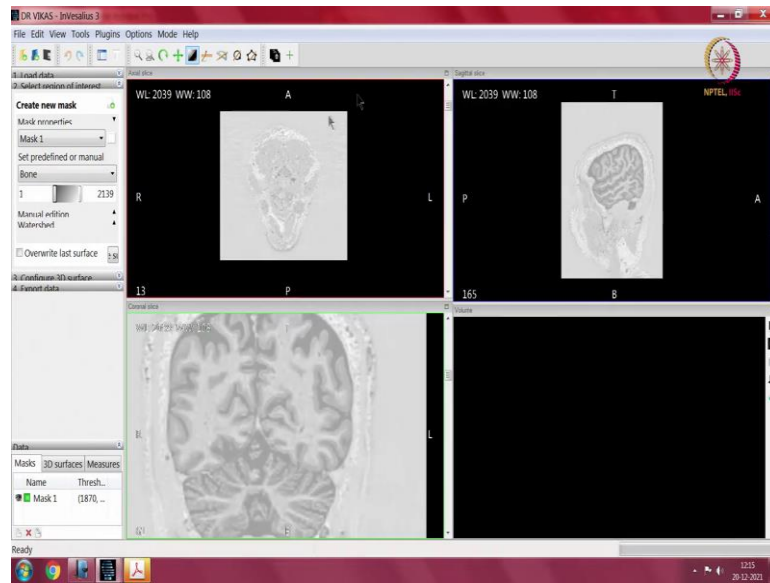


So, the tentorium separates the cerebrum some cerebellum splits the skull into supratentorial and infratentorial. So, here we can see the differences between the two parts, this is the cerebrum not the architecture of the cerebellum. So, this is cerebellum, cerebrum.

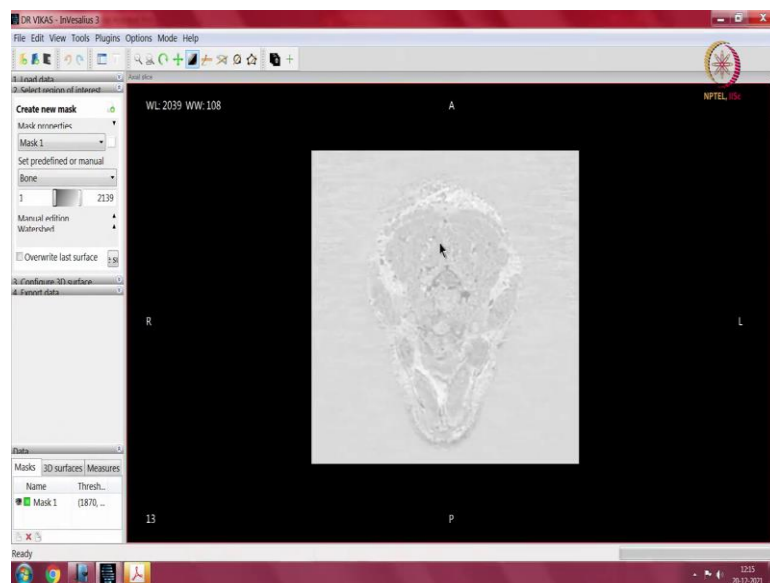
(Refer Slide Time: 18:30)



(Refer Slide Time: 18:31)

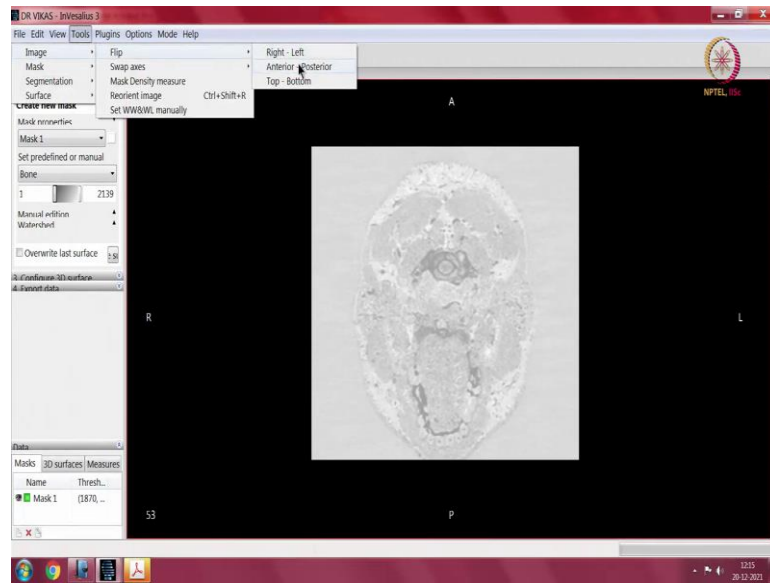


(Refer Slide Time: 18:34)

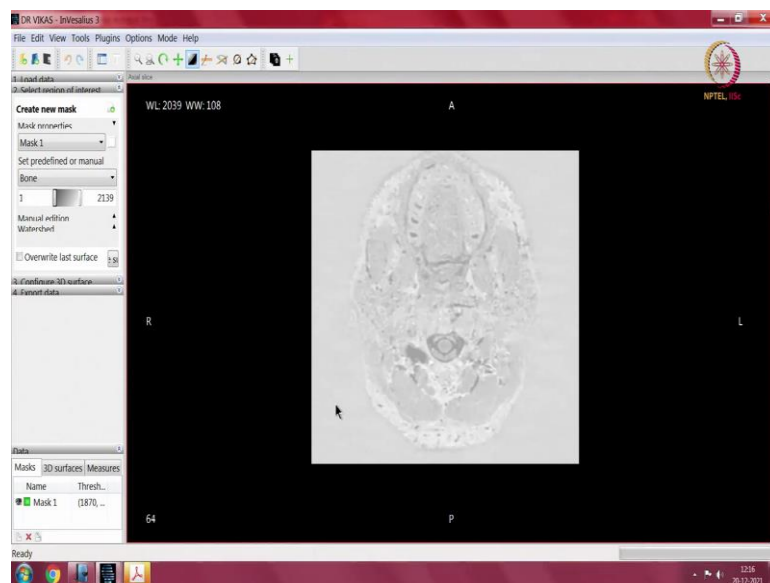


Fine, so generally we would discuss anatomy in the context of axial sections.

(Refer Slide Time: 18:40)

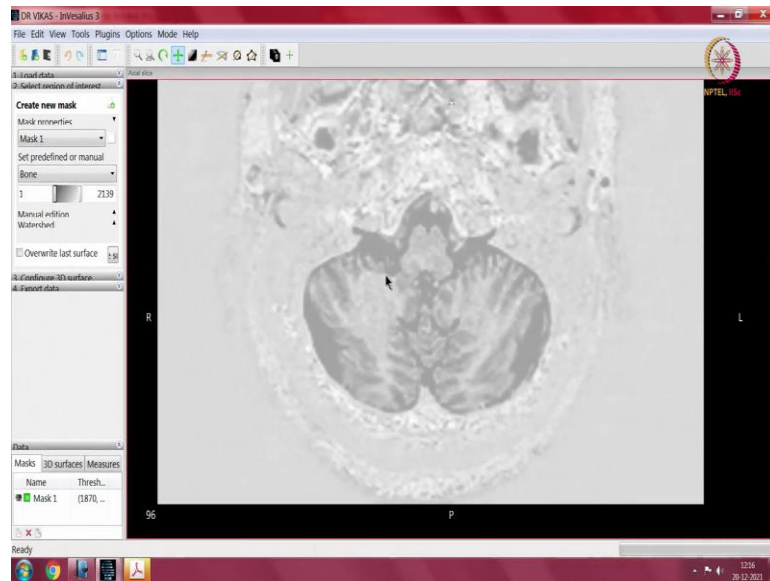


(Refer Slide Time: 18:46)



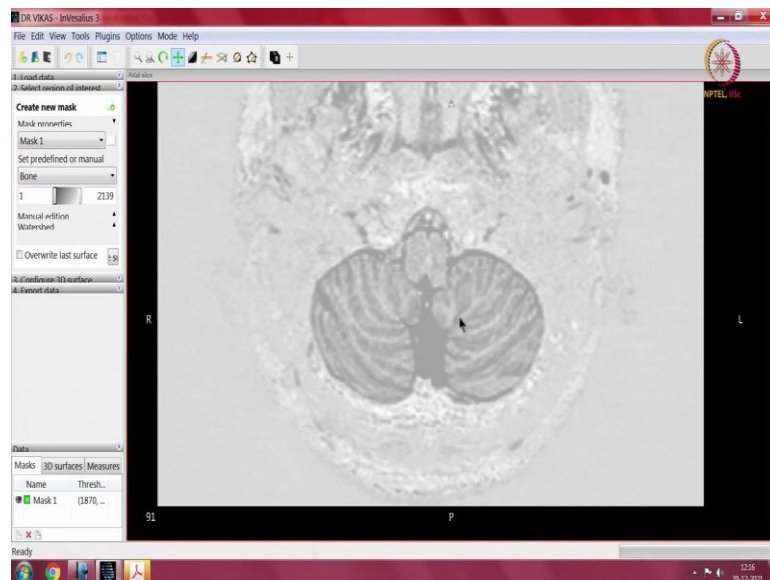
So, axial sections are the primary way in which we would discuss anatomy.

(Refer Slide Time: 18:51)



So, we start with something which are obvious. So, this is the cerebellum. So, this whole stuff is the cerebellum. Two hemispheres like in the cerebrum.

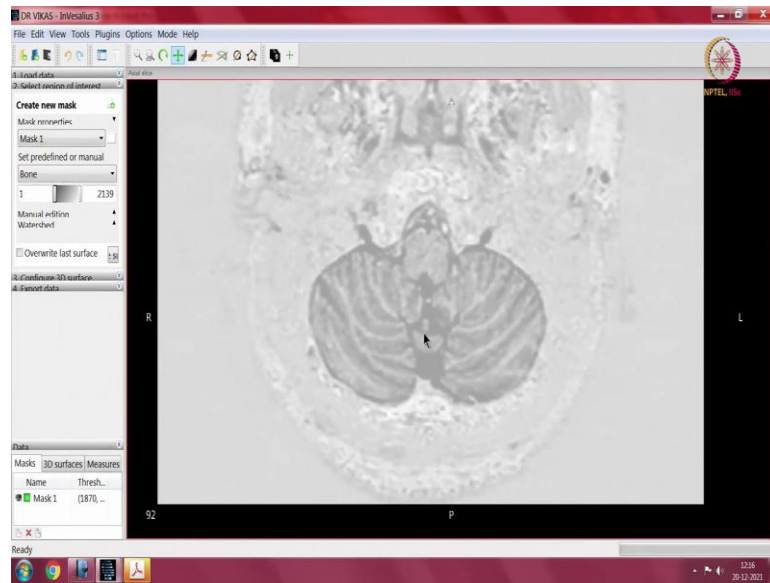
(Refer Slide Time: 19:12)



You can make it make out very clearly. These two small structures over here are called the tonsils.

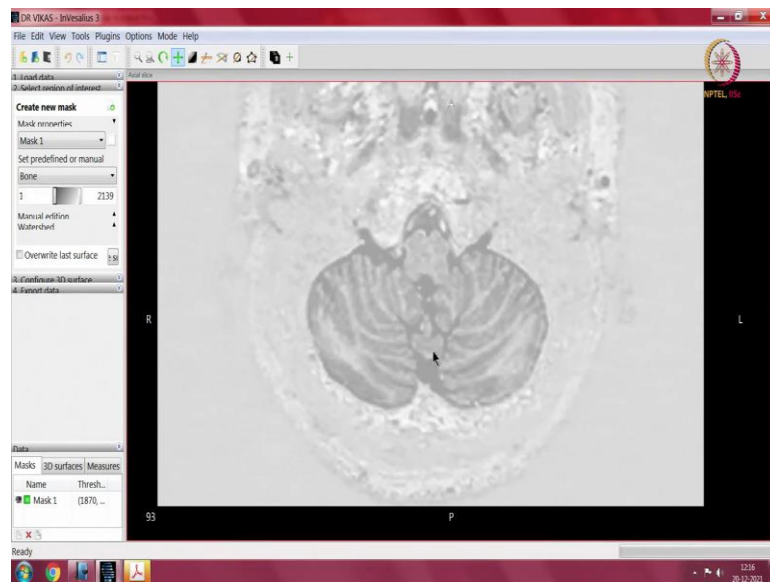


(Refer Slide Time: 19:23)



Tonsil, we come up a little bit and this thing is the uvula. So, these are things which I shown in my 3D anatomy class.

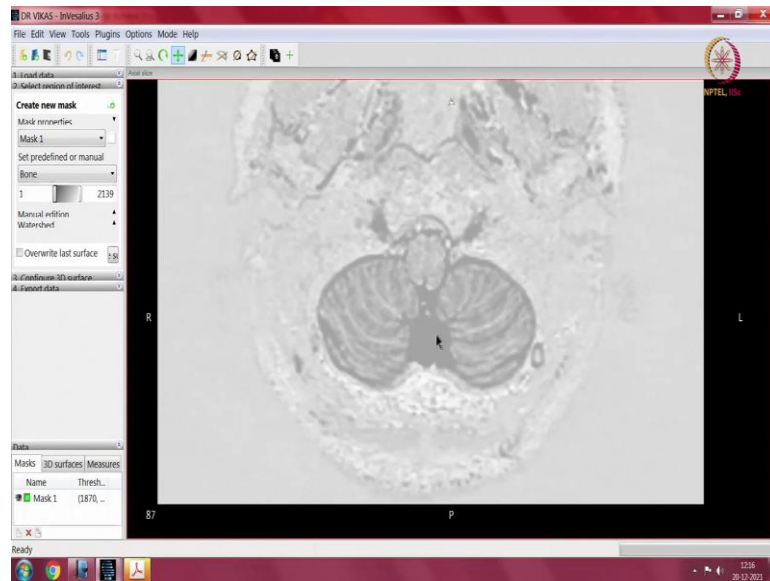
(Refer Slide Time: 19:34)



So, the same things in 2D how they look? So, this is uvula.

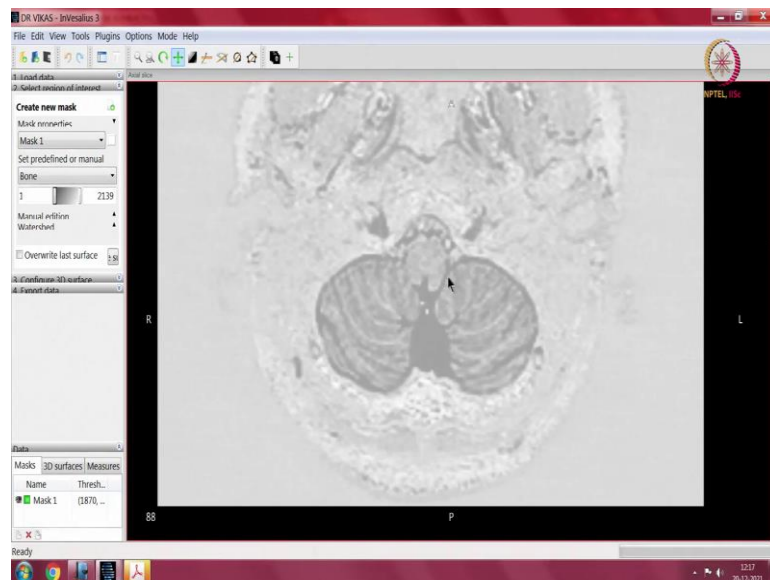


(Refer Slide Time: 19:40)



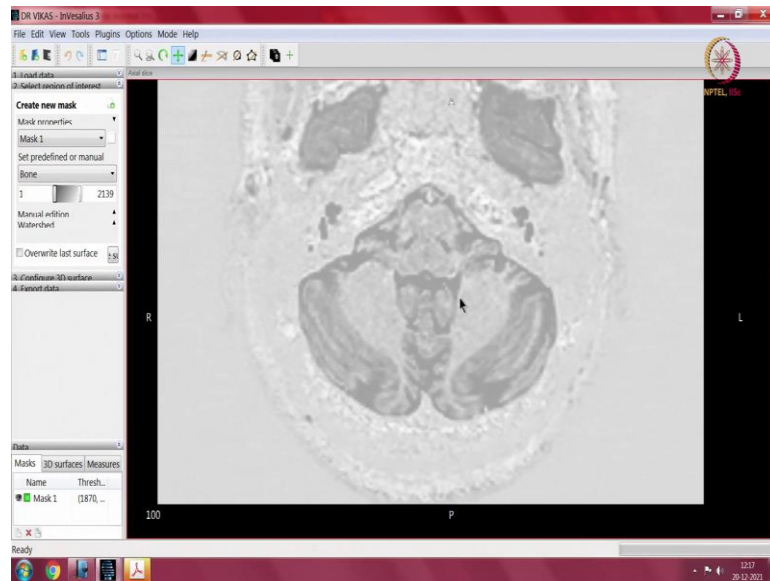
Then these things down here, these bulges here are the tonsil. This is cerebellar hemisphere.

(Refer Slide Time: 19:48)



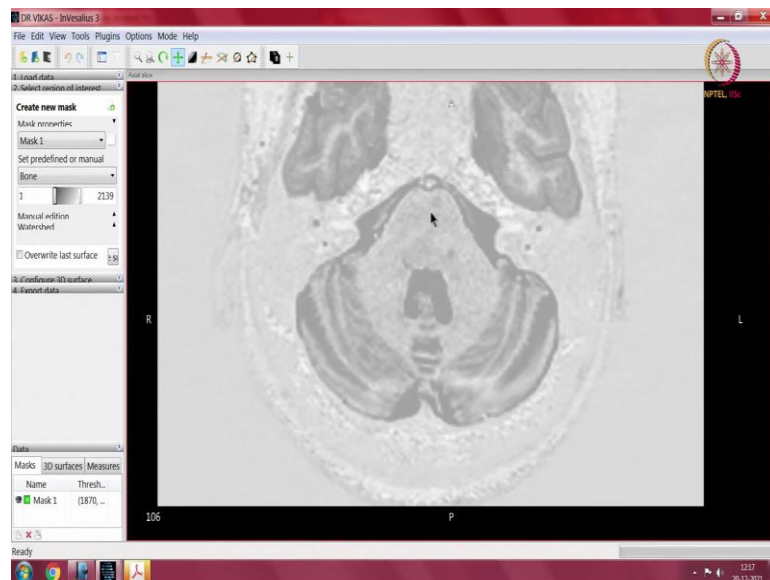
This is the left cerebellar hemisphere, this is the right cerebellar hemisphere its by convention. So, and this round structure over here is the brainstem. Not very obvious see which is one of the reasons I did not want to start teaching anatomy through sectional imaging.

(Refer Slide Time: 20:08)



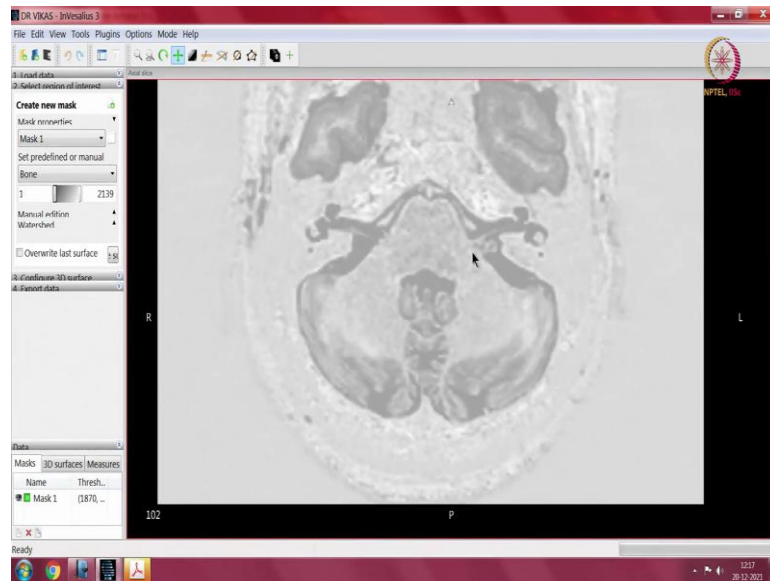
Sectional imaging is advanced imaging, because you need to understand what is there in 3D before you actually interpret what is there in 2D.

(Refer Slide Time: 20:10)



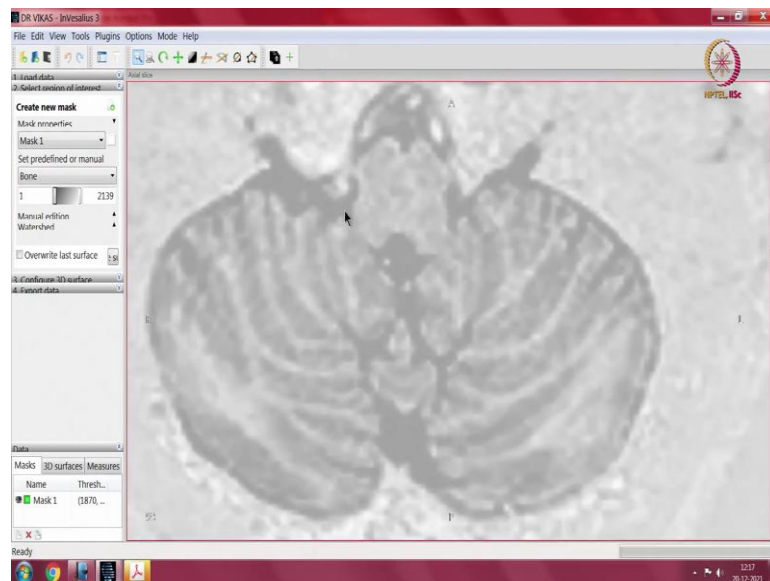
So, now, this whole stuff is the brainstem, and you can make out that there are no distinct boundaries between brainstem and cerebellum. Because the brainstem and the cerebellum communicate through things called as the peduncle.

(Refer Slide Time: 20:22)



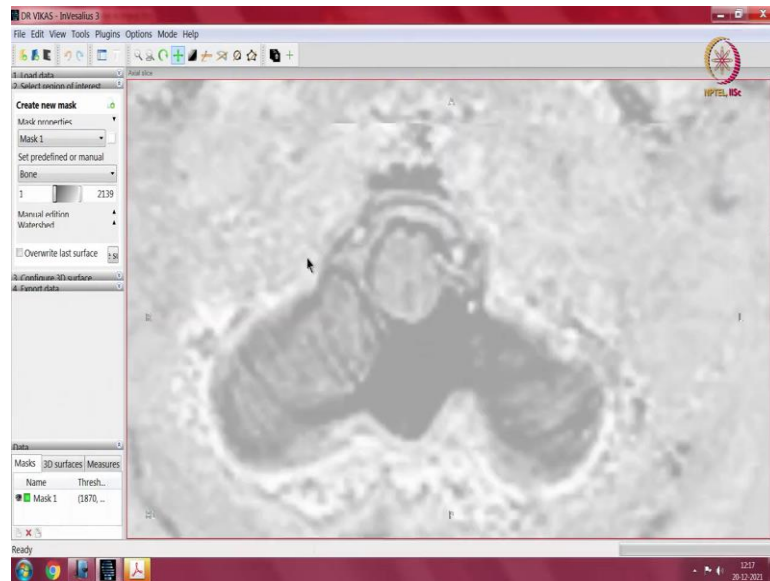
So, this is the communication between the brainstem and the peduncles.

(Refer Slide Time: 20:30)



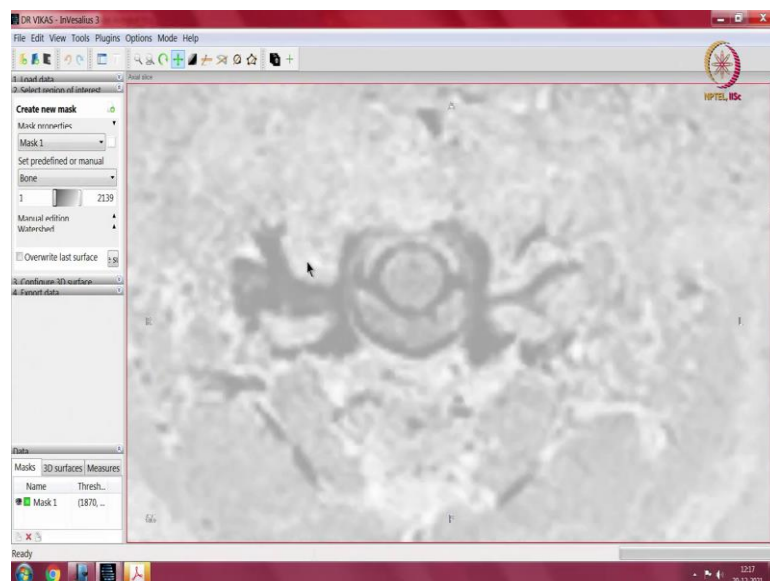
Now again going back to what I taught you earlier. How do you recognize various parts of the brainstem?

(Refer Slide Time: 20:42)

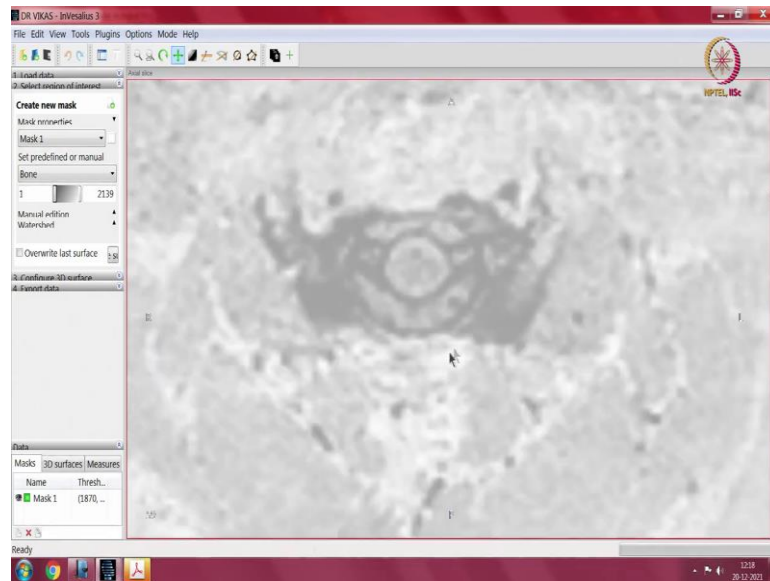


Yeah so, this is lower down.

(Refer Slide Time: 20:46)

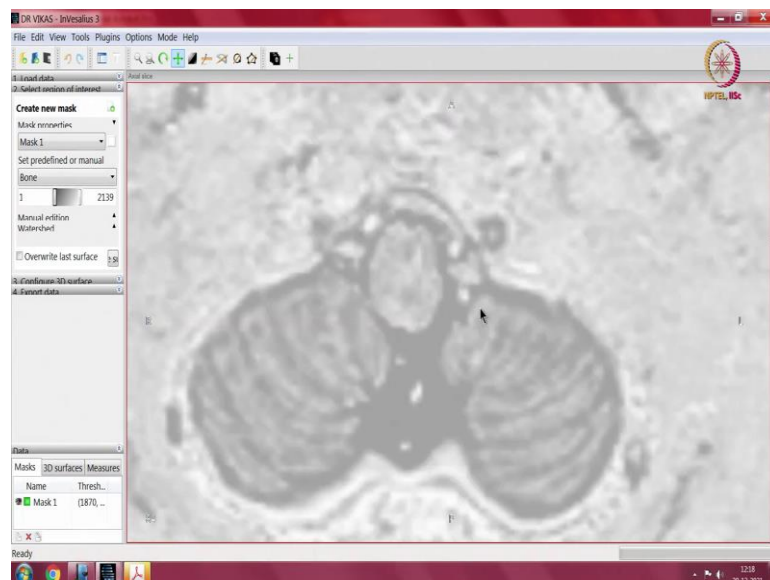


(Refer Slide Time: 20:48)



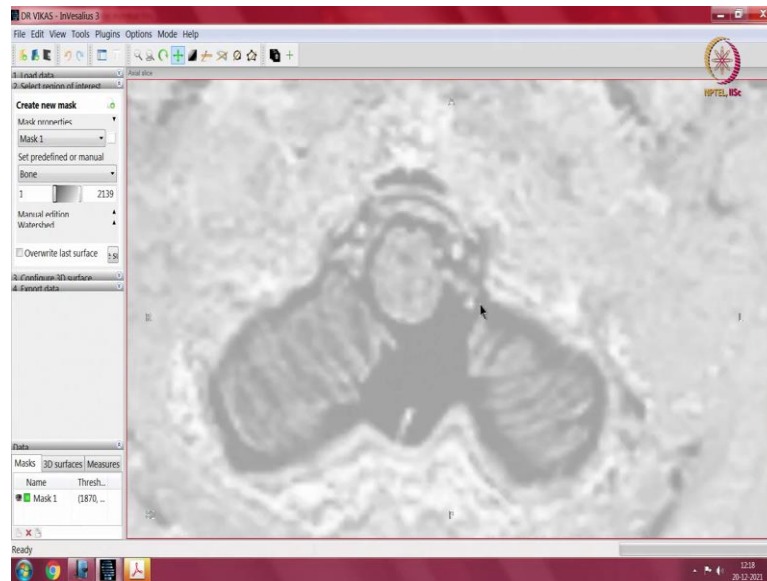
So, we again coming down this is almost the neck, this is spinal cord. So, this white stuff is the spinal cord. You can imagine that its resolution is not adequate in spite of the kind of imaging technique.

(Refer Slide Time: 21:00)



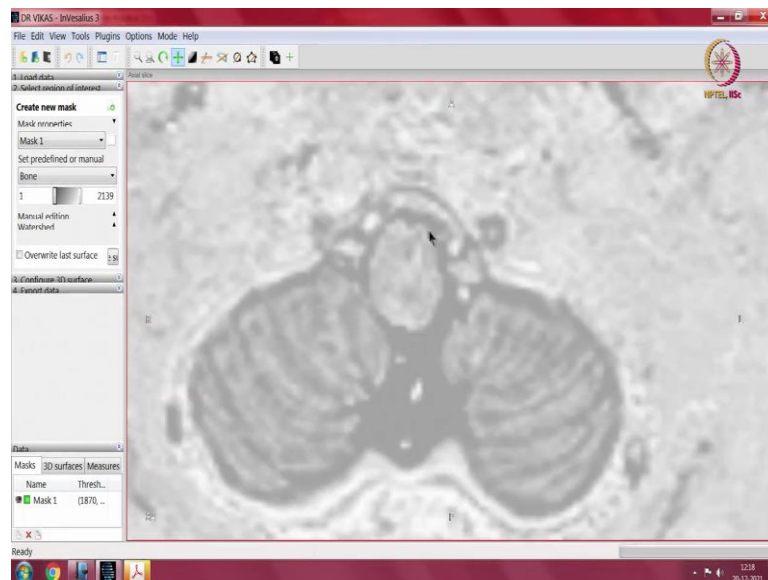
You can see the pixelations happening at this magnification.

(Refer Slide Time: 21:04)



These are very high resolutions. In fact, the reason I am using this imaging is because its been acquired using the best possible techniques for white gray differentiation.

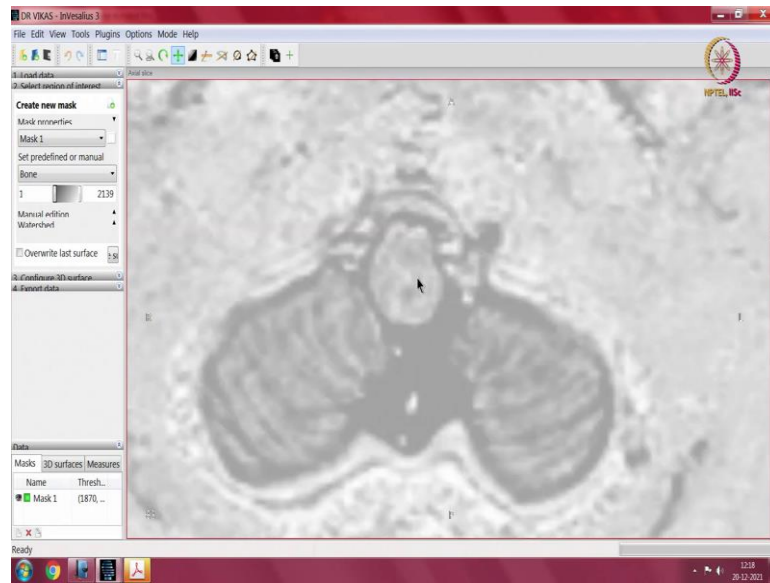
(Refer Slide Time: 21:13)



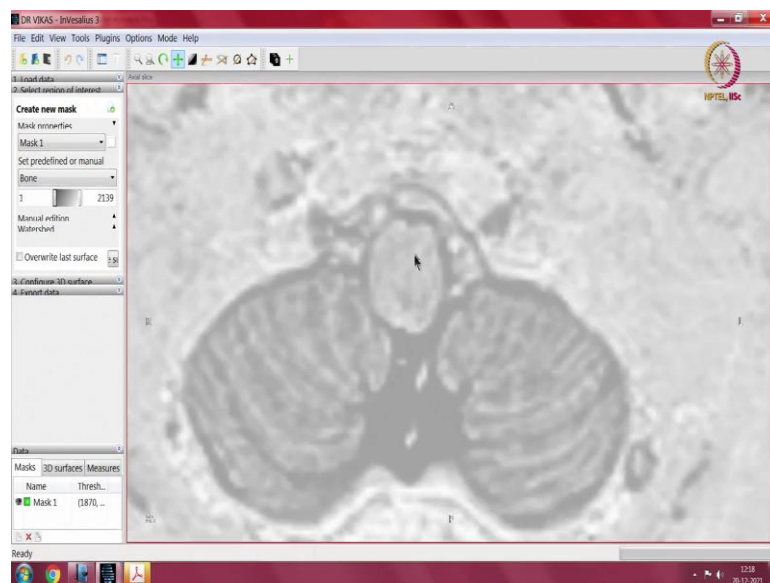
So, brainstem. So, here lower down spinal cord continues into the brainstem. So, if this is the brainstem, then what part of the brainstem this would be the medulla. Where medulla which continues down as the spinal cord.



(Refer Slide Time: 21:25)

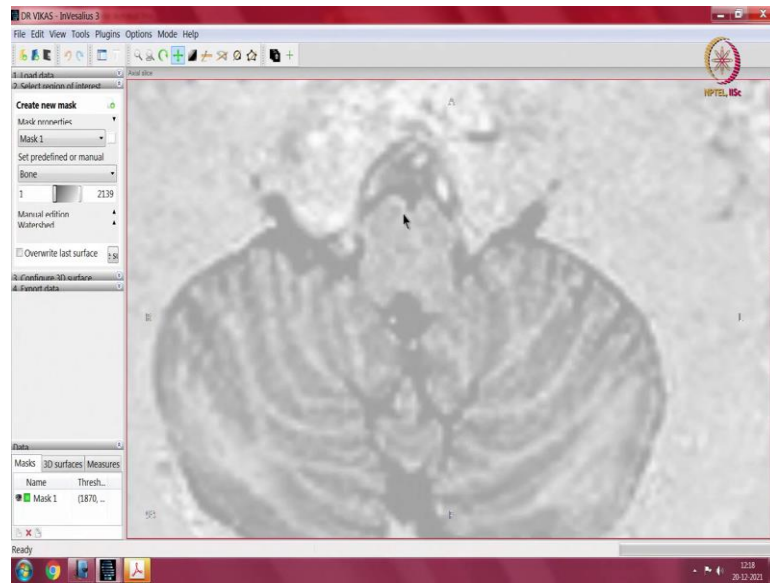


(Refer Slide Time: 21:28)



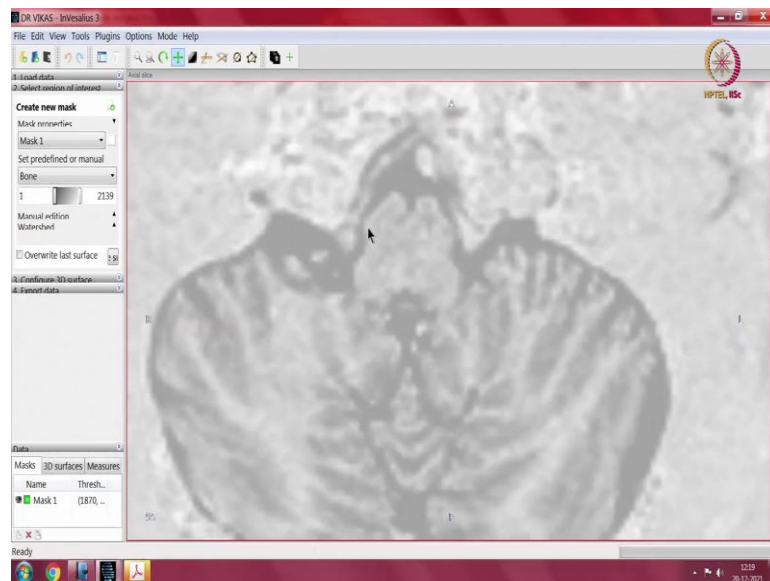
So, anteriorly would be the midline small deflection where which is if which is the fissure. On either side these bulges which are seen bulges which are seen are the pyramids ok.

(Refer Slide Time: 21:45)



So, this would be the pyramids again.

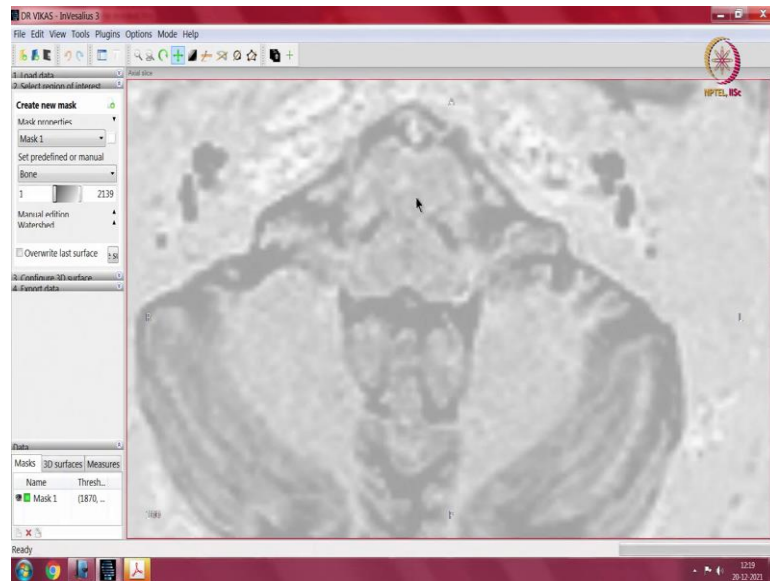
(Refer Slide Time: 21:48)



Pyramid the pyramid.

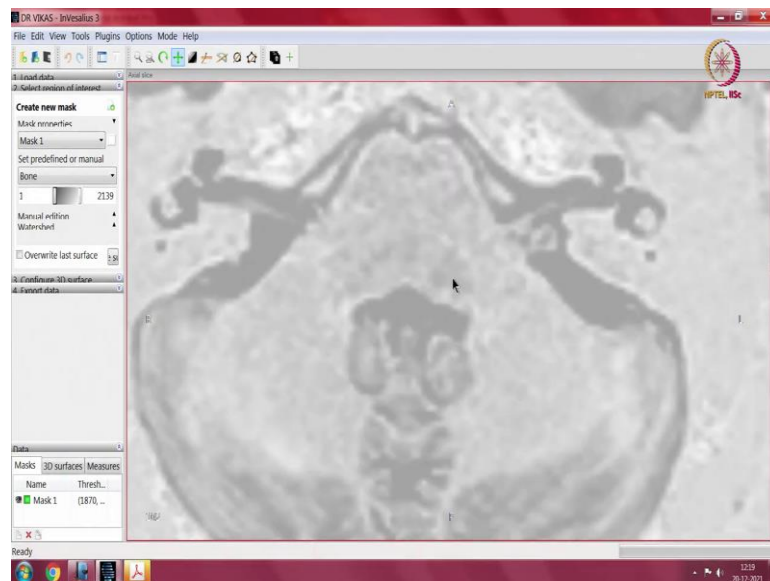


(Refer Slide Time: 21:52)



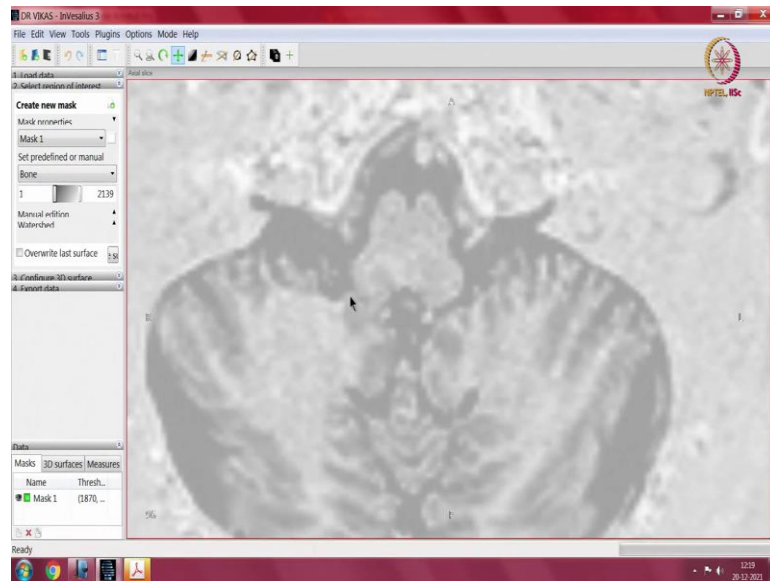
Yeah, now you can see this transition. So, it is jumping and becoming bigger.

(Refer Slide Time: 22:00)



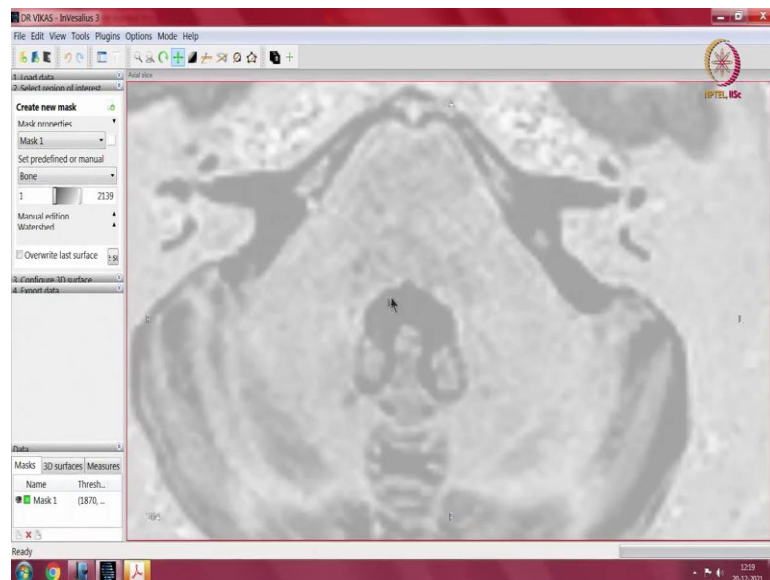
So, this part this whole part would become the pons. This is the pons up to here. So, pons is the place where there are connections with the cerebellum.

(Refer Slide Time: 22:15)



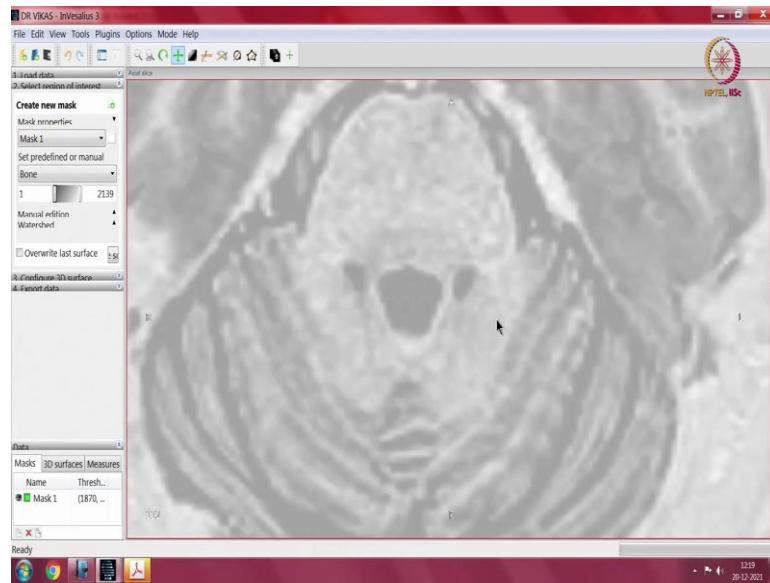
If you go back there are no distinct connections with the cerebellum here, you can see that there is a boundary here and then there is a clear boundary here.

(Refer Slide Time: 22:24)



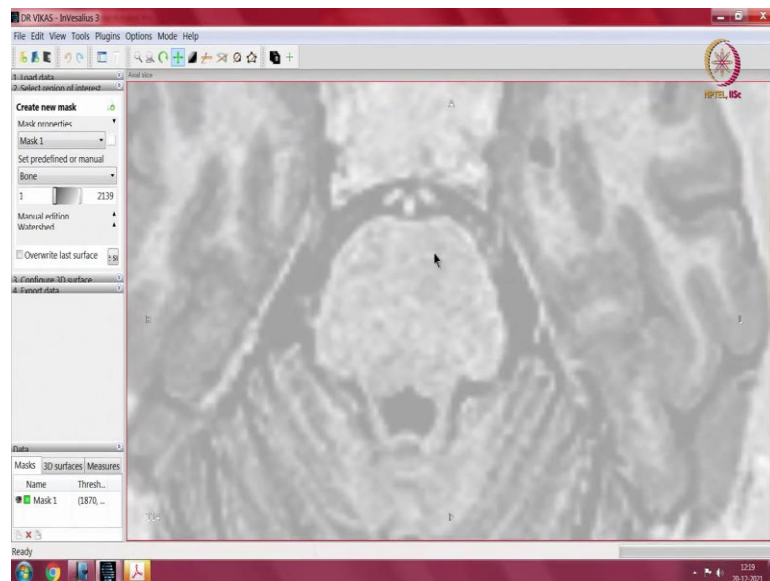
So, when it comes to the pons its obvious that the pons communicates with the cerebellum. So, these are through something called cerebellar peduncles superior middle and inferior.

(Refer Slide Time: 22:32)



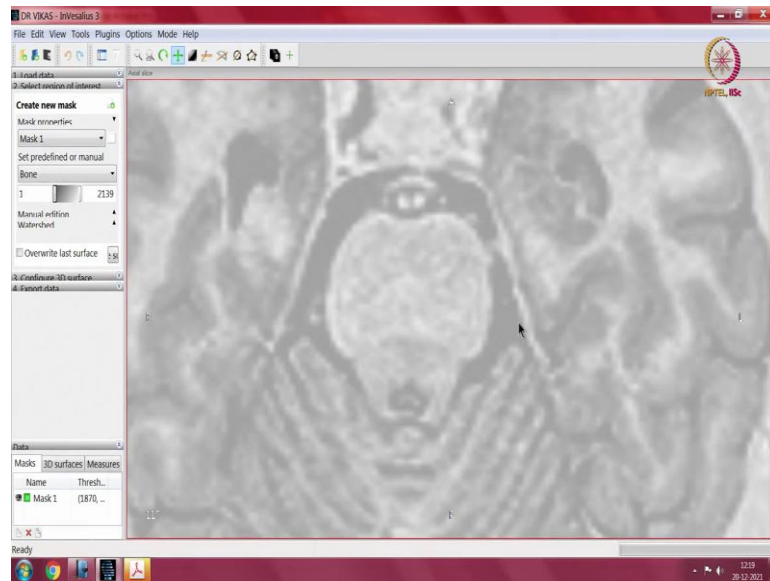
So, this is the cerebellar peduncle we come up.

(Refer Slide Time: 22:35)



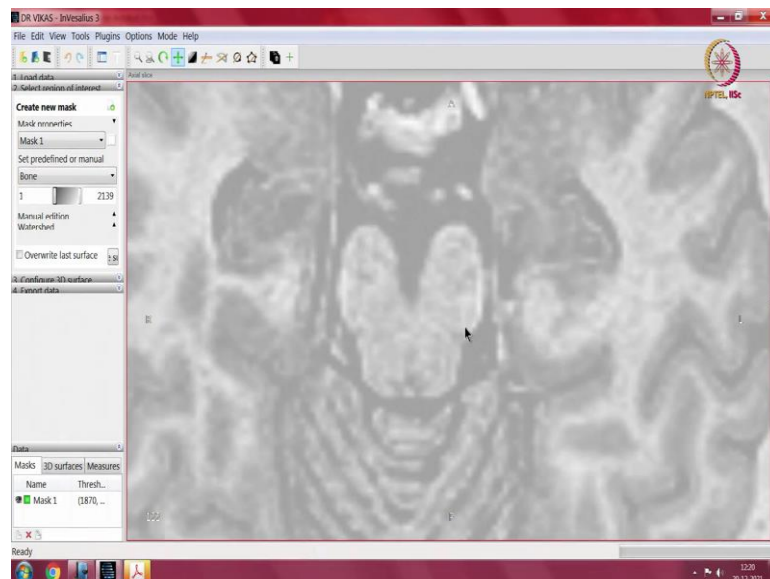
This is still the pons posterior fossa.

(Refer Slide Time: 22:42)



And this white stuff which is seen as the petrous bone yeah.

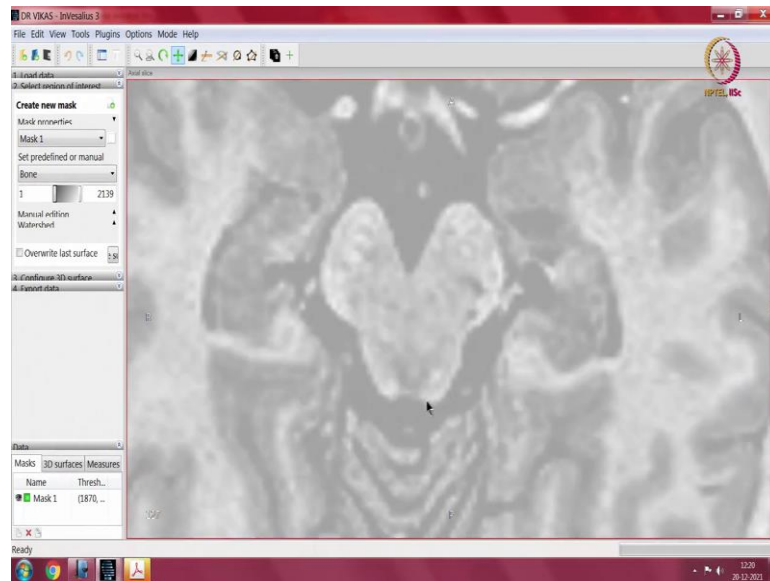
(Refer Slide Time: 22:48)



So, I think this structure should be familiar to all of you by now. So, this is the midbrain.

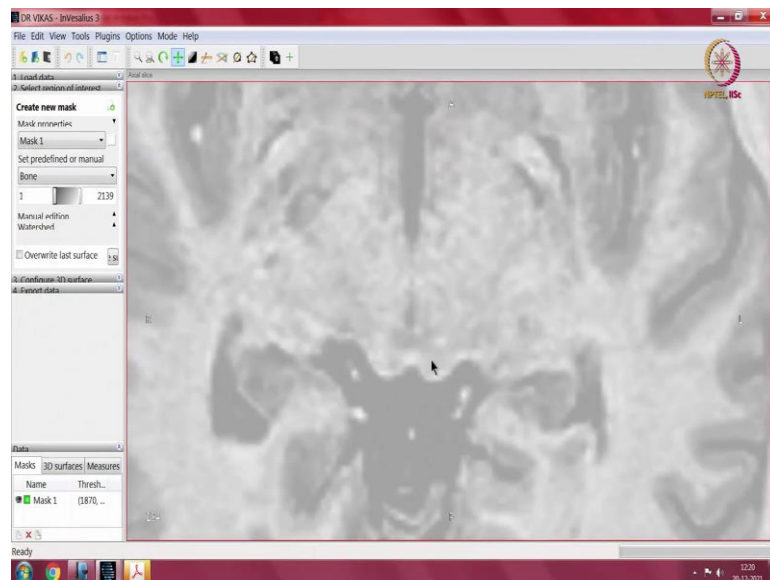
So, we started from below we come up from medulla to the pons.

(Refer Slide Time: 23:03)



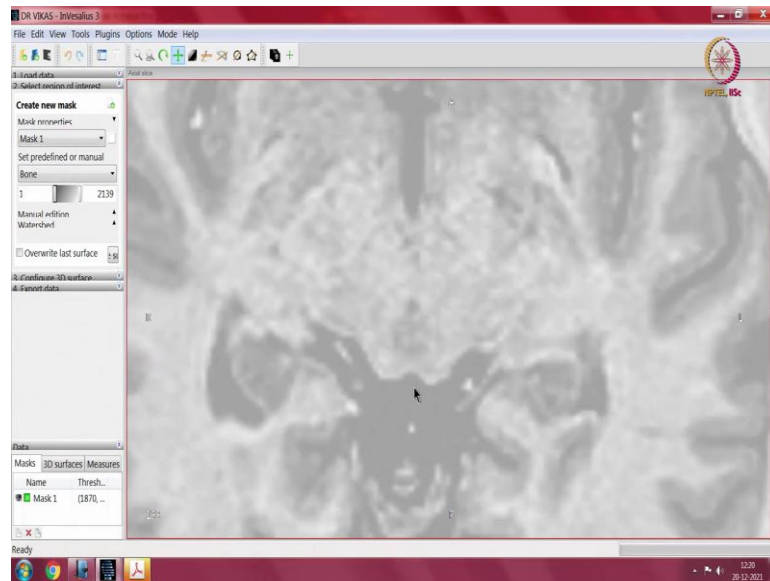
And to the midbrain. Midbrain you can see small bulges behind this one bulge here and this one bulge over here. So, they are the colliculi right.

(Refer Slide Time: 23:16)



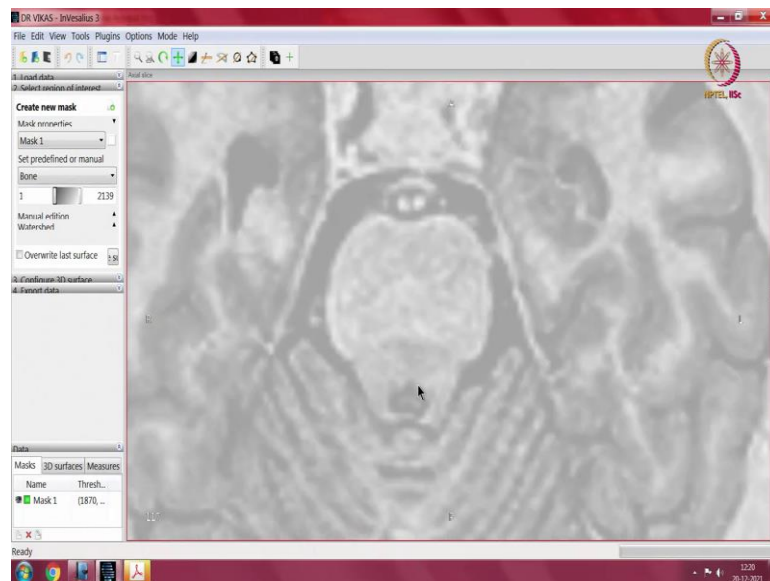
And so, that is the; that is the yeah that would be the superior colliculi which is the bulge over here.

(Refer Slide Time: 23:24)



And this should be the inferior colliculi.

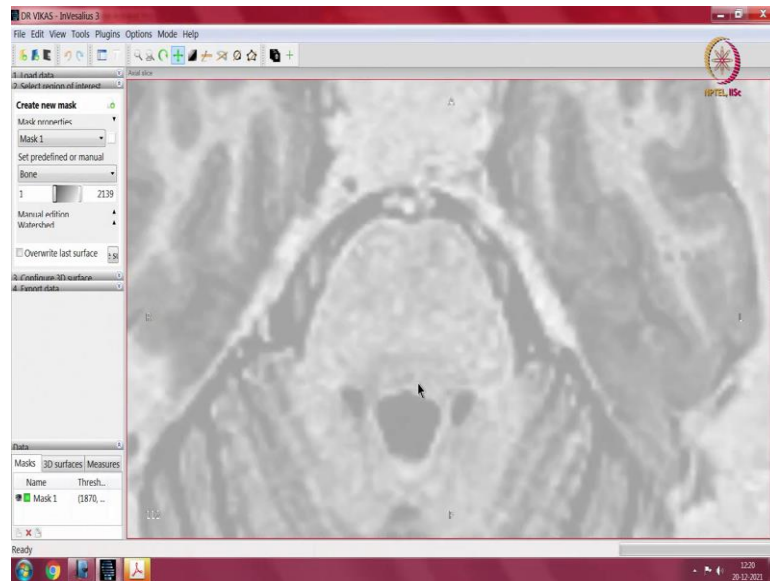
(Refer Slide Time: 23:30)



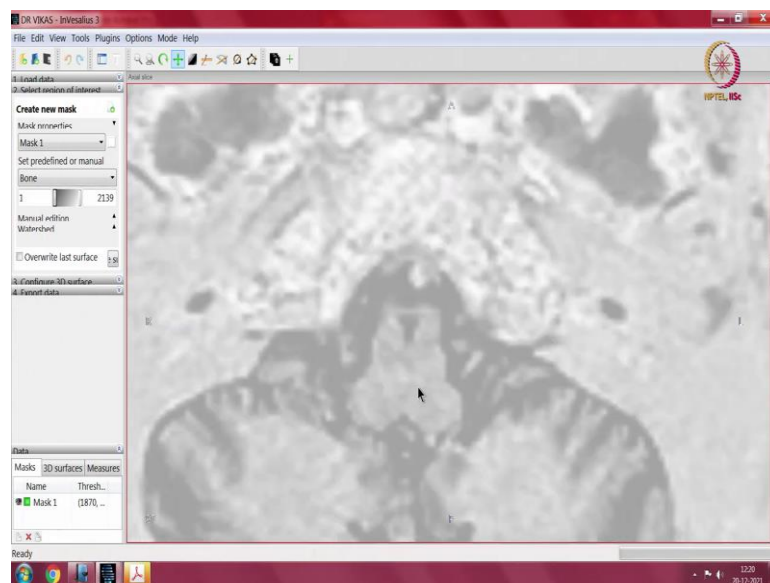
So, that is how the colliculi, and that is the midbrain.



(Refer Slide Time: 23:31)

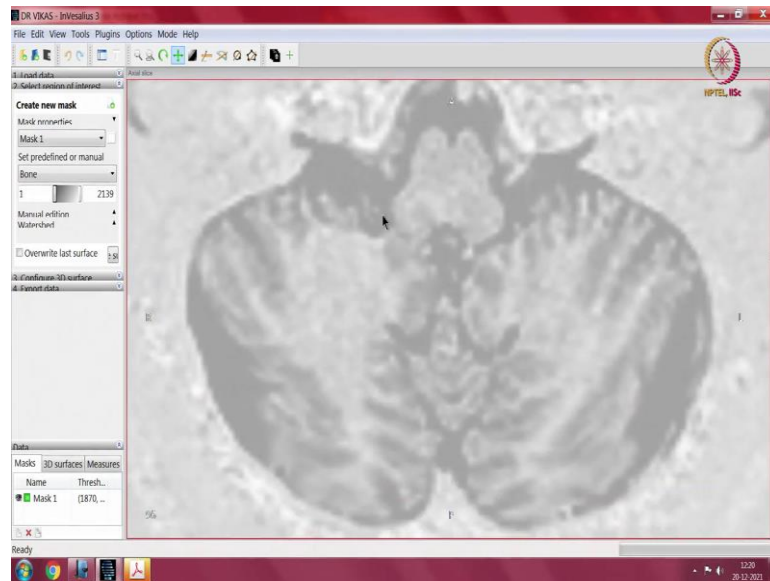


(Refer Slide Time: 23:34)



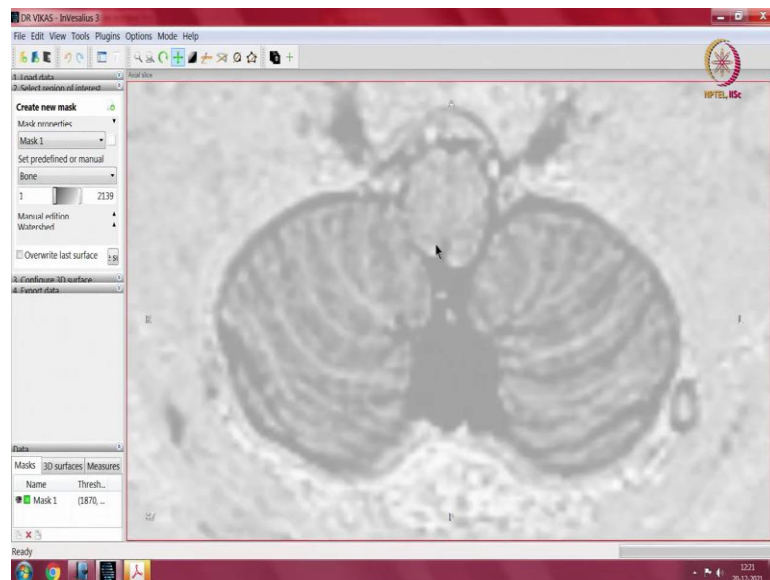
Midbrain, pons and lower down medulla.

(Refer Slide Time: 23:37)



Lower down medulla, cerebellum is here left hemisphere, right hemisphere. So, axial sections starting from below.

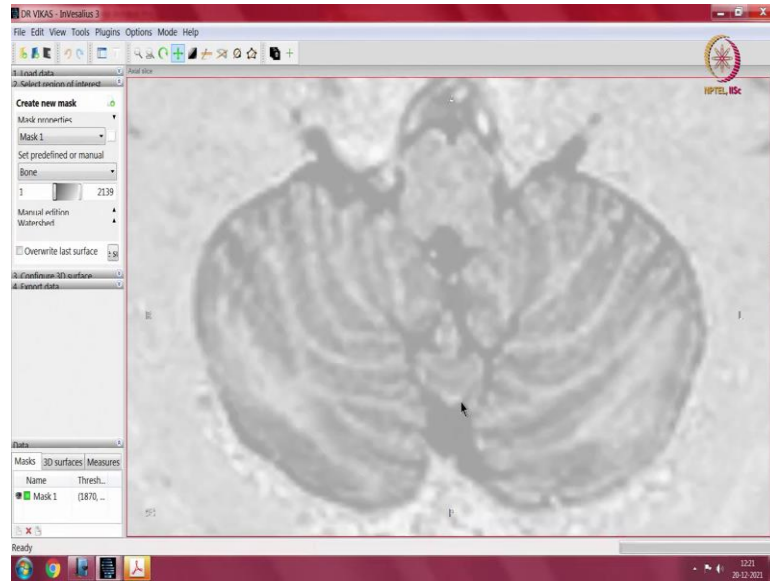
(Refer Slide Time: 23:51)



Cerebellum, medulla, tonsil of the cerebellum; tonsil of the cerebellum, the hemispheres of the cerebellum and the medulla.

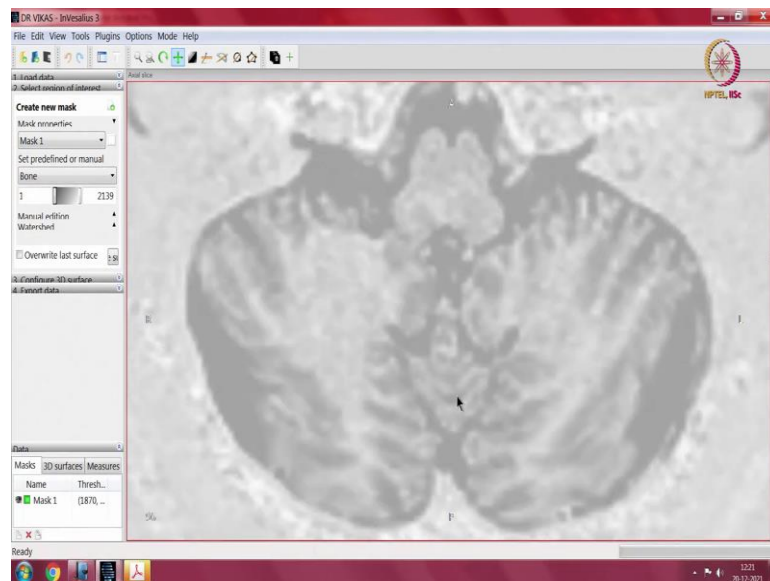

(Refer Slide Time: 24:07)



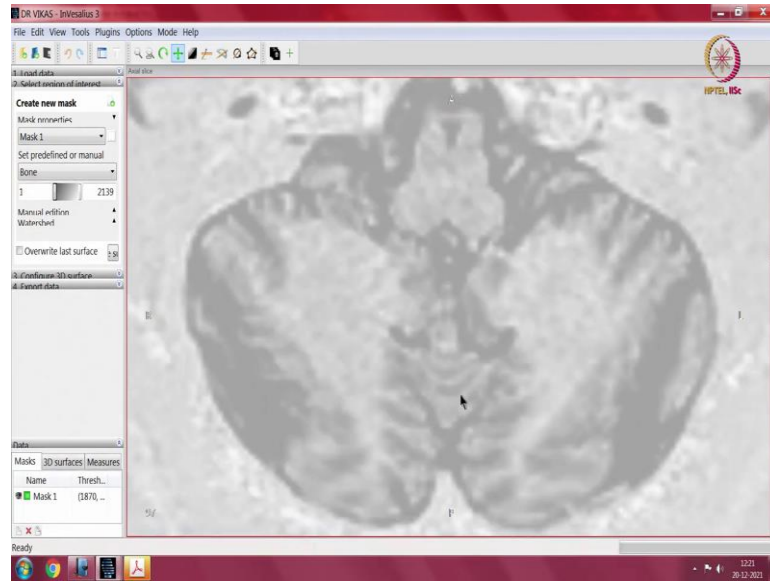
Coming up you can see the uvula come into focus which is the central part.

(Refer Slide Time: 24:10)



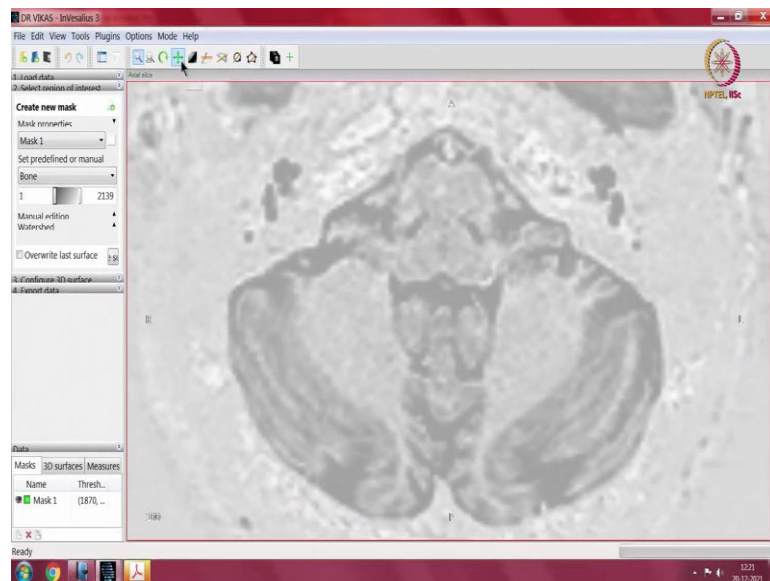
This upper the lower part is the uvula.

(Refer Slide Time: 24:13)



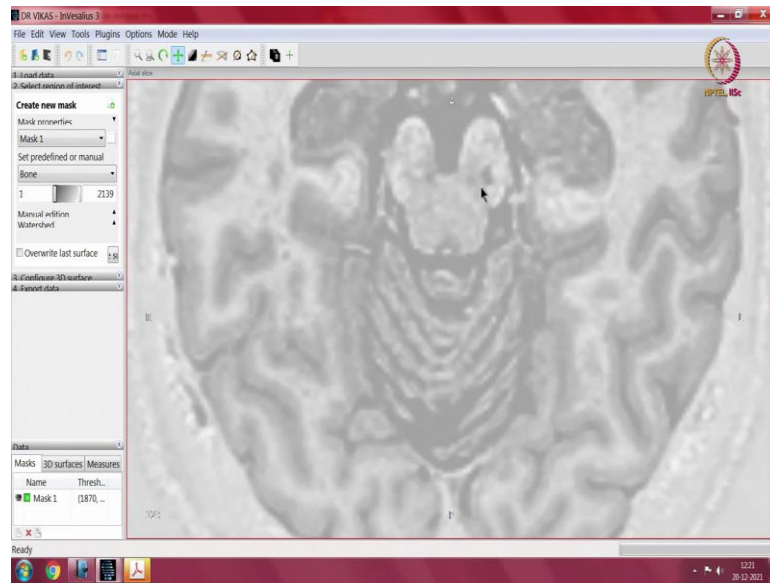
But the upper part is called the vermis which connects both the cerebellar hemispheres.

(Refer Slide Time: 24:23)



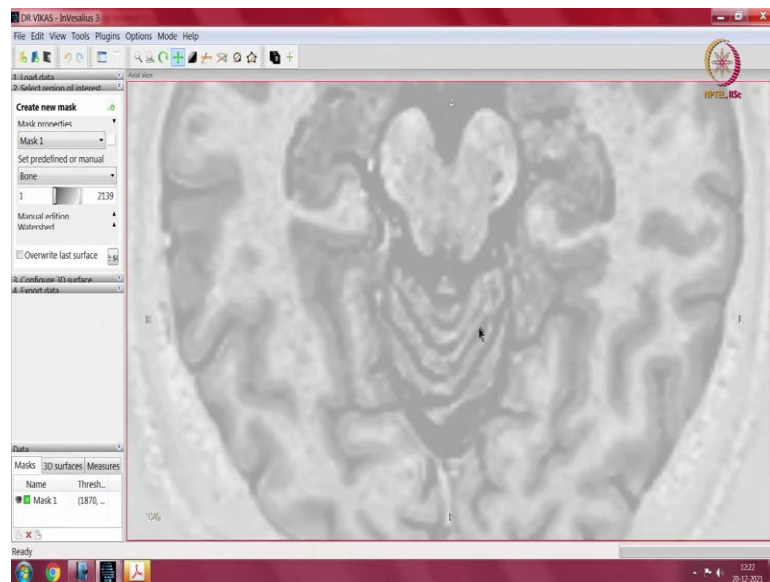
So, this is the vermis cerebellar hemisphere, cerebellar hemisphere then we come to the pons.

(Refer Slide Time: 24:41)



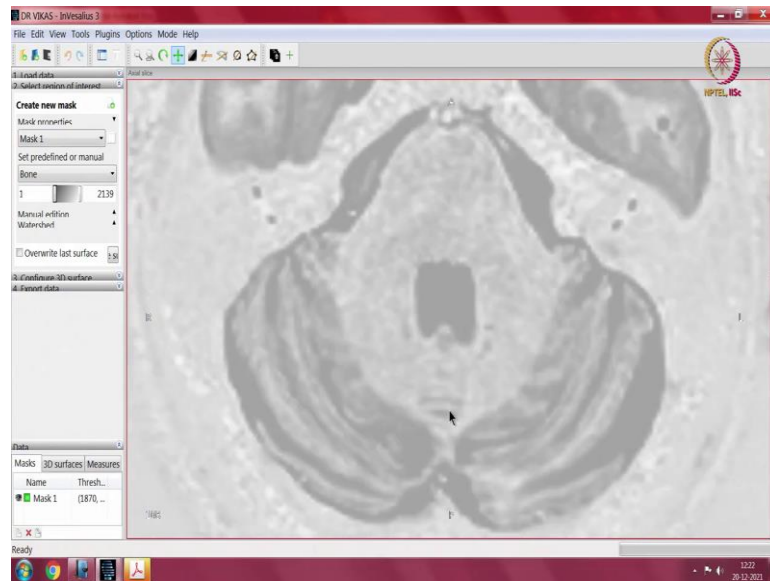
And coming up yeah that split which happens. So, this is the pons and then suddenly we are in the midbrain.

(Refer Slide Time: 24:49)



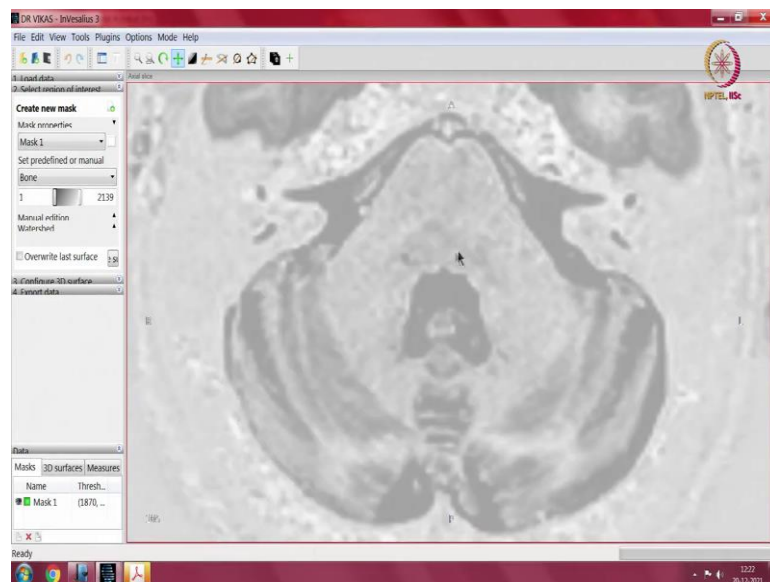
So, midbrain is still part of the cerebellum scene. So, this gap through which the brainstem and the cerebellar is called as the tentorial incisura.

(Refer Slide Time: 25:00)



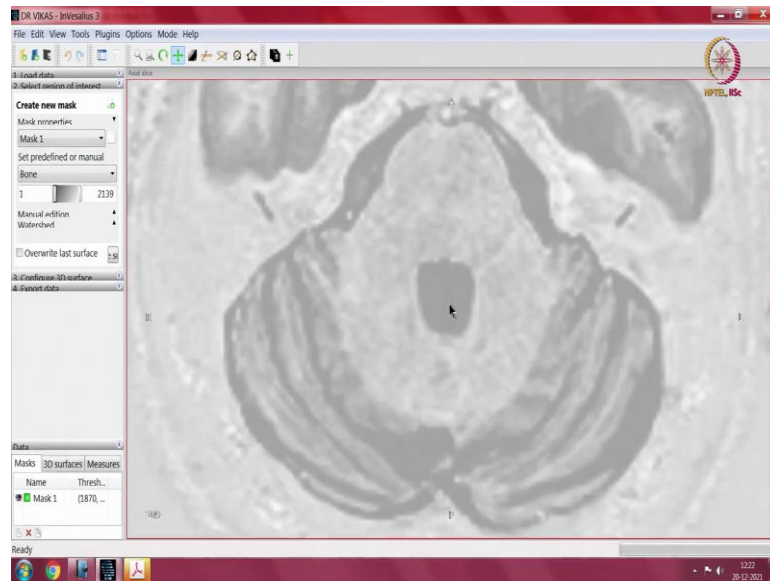
So, opening in the tentorium its opening in the tentorium. The tentorium in turn splits between the upper part which is the cerebrum and the lower part which is the posterior fossa containing the cerebellar hemispheres.

(Refer Slide Time: 25:17)



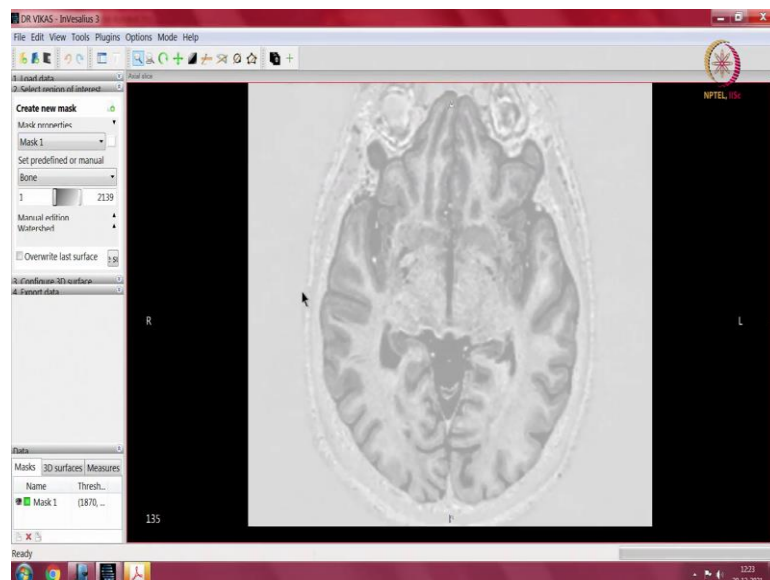
Another structure seen black in color. So, this thing is the ventricle. So, which ventricle it would be? It would be the fourth ventricle. Because we are starting from the base and coming up.

(Refer Slide Time: 25:27)



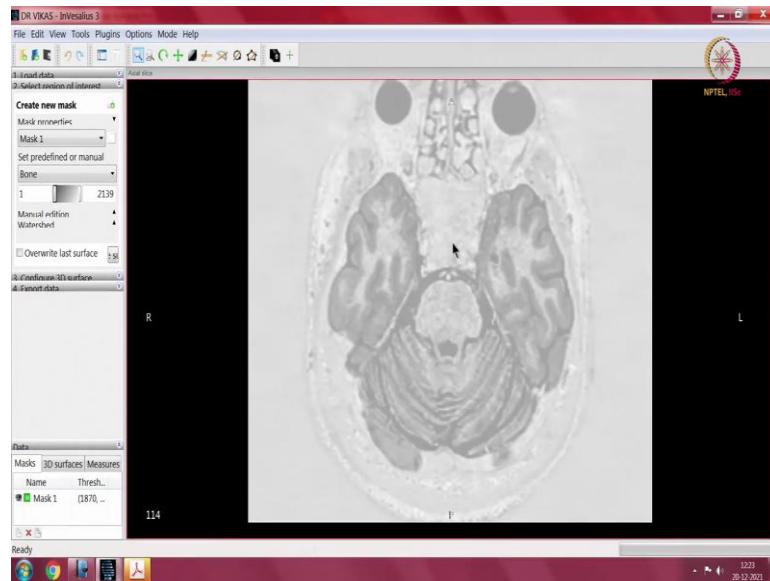
So, that is the fourth ventricle. So, what happens to the fourth ventricle? We trace it up trace it up and just above you see that it becomes a small cavity over here it's called the aqueduct right.

(Refer Slide Time: 25:44)



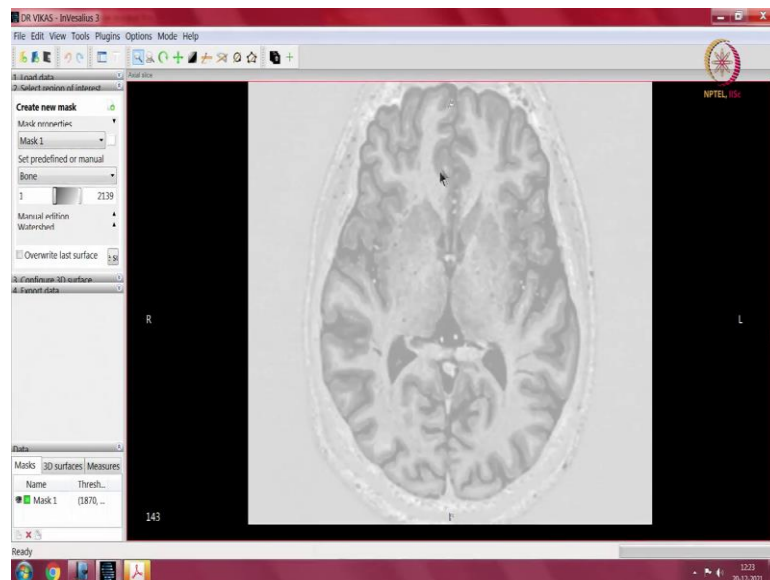
So, what happens above is the cerebrum comes into place. So, we go back from below.

(Refer Slide Time: 25:59)



On either side the first structures which you see almost in relation to the eye are the temporal lobes. So, this is the left temporal lobe, right temporal lobe yeah.

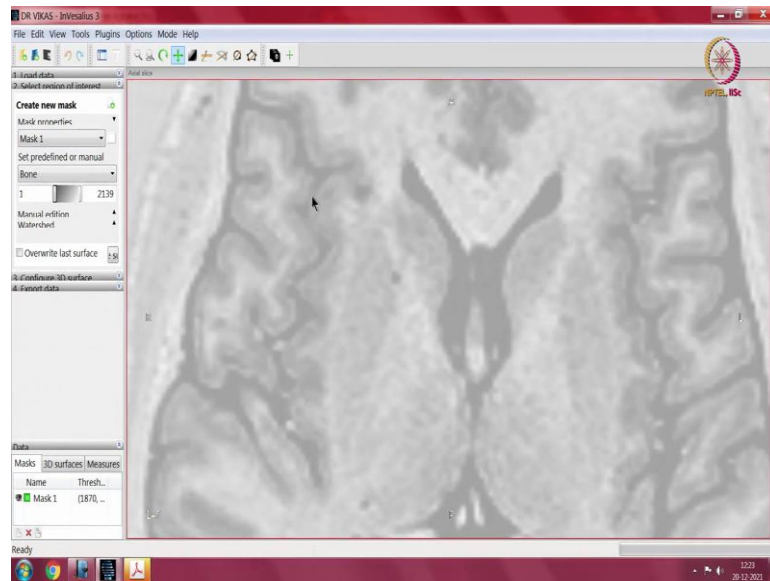
(Refer Slide Time: 26:17)



So, this is another place. So, this would be the frontal lobe, parietal lobe, occipital lobe. Another thing which I would like you to appreciate is a small gap here, small gap here.

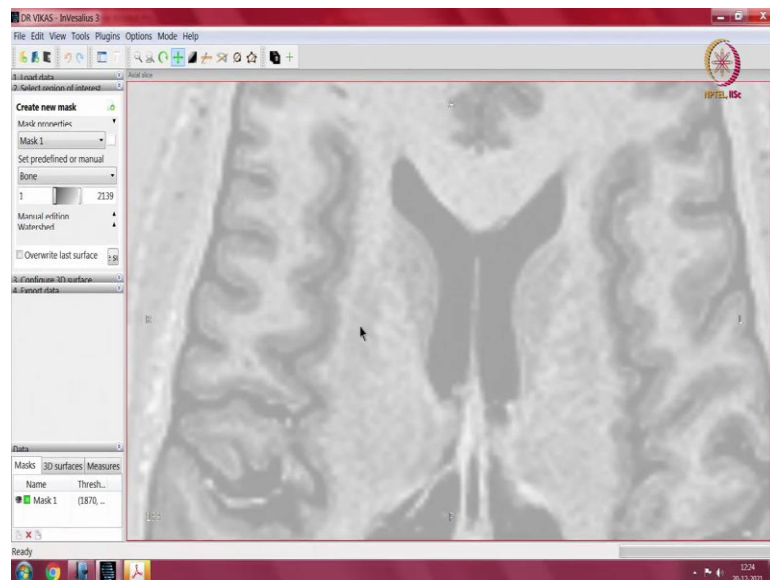


(Refer Slide Time: 26:44)



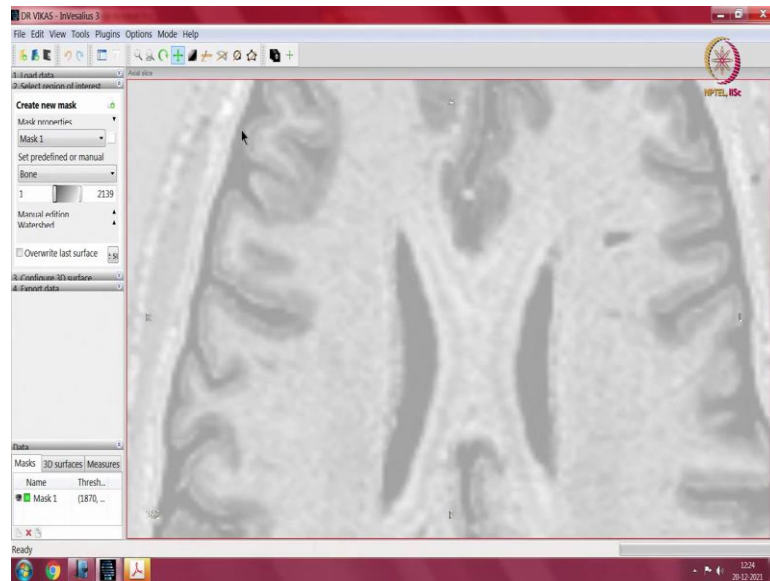
Small gap here and that gap is the insular cortex. Same on the opposite side. So, insula is surface which is buried under the brain.

(Refer Slide Time: 26:59)



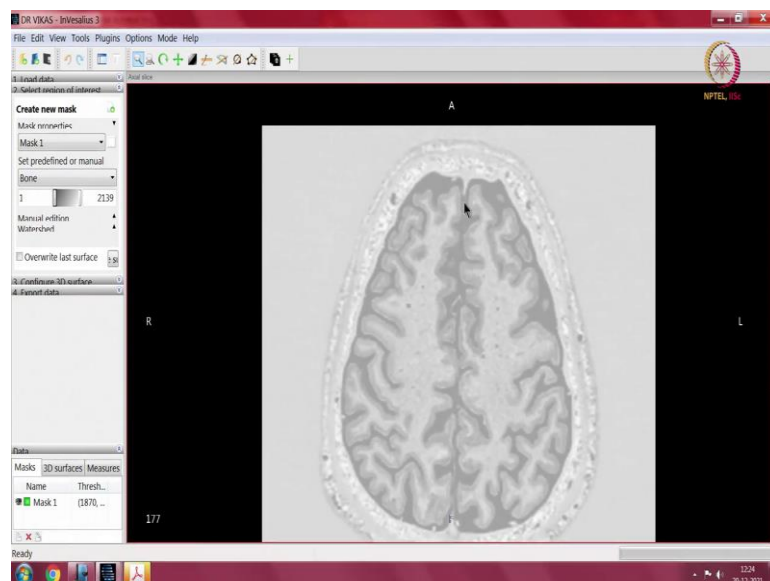
So, there is brain tissue here, there is brain tissue here. And in between is this thing called as the insula.

(Refer Slide Time: 27:08)



And so, that is the parts of the cerebrum from the outside.

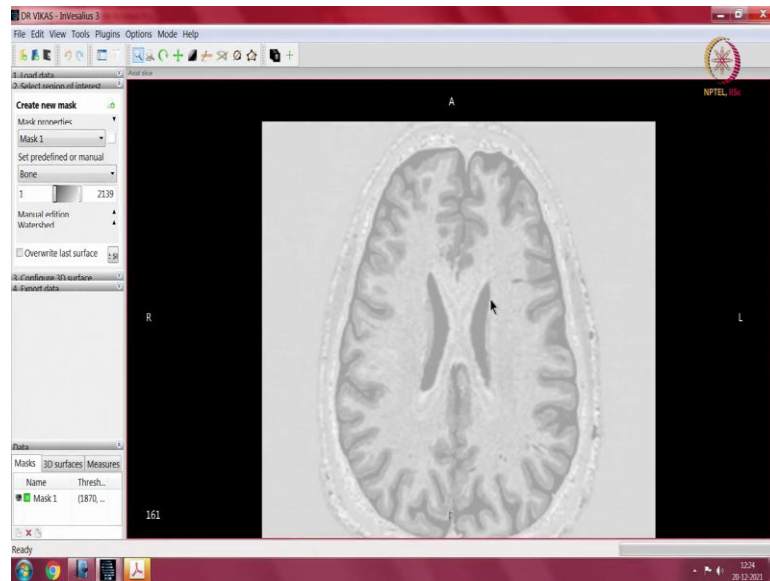
(Refer Slide Time: 27:24)



When we come up, we can see the clear separation between the two cerebral hemispheres. This is the beginning of the falx, which separates its dura, which separates the two hemispheres. And then there is this black gap in between which is the space between the two hemispheres.

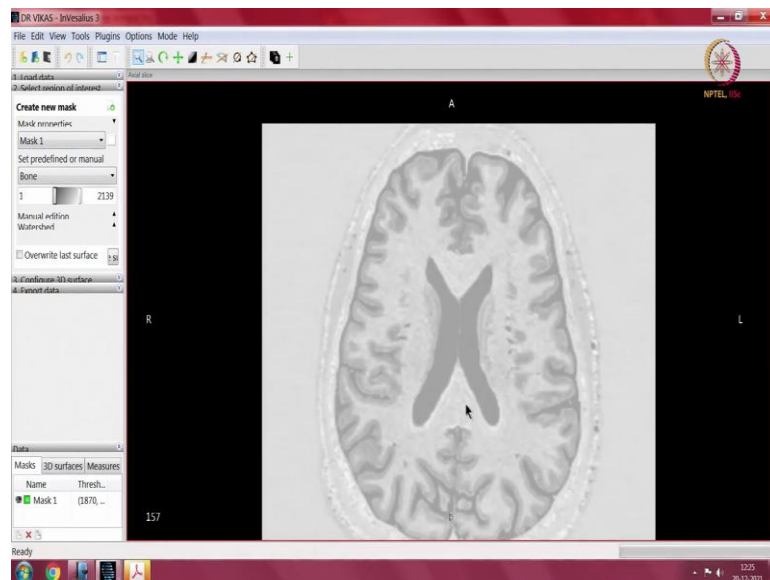


(Refer Slide Time: 27:44)



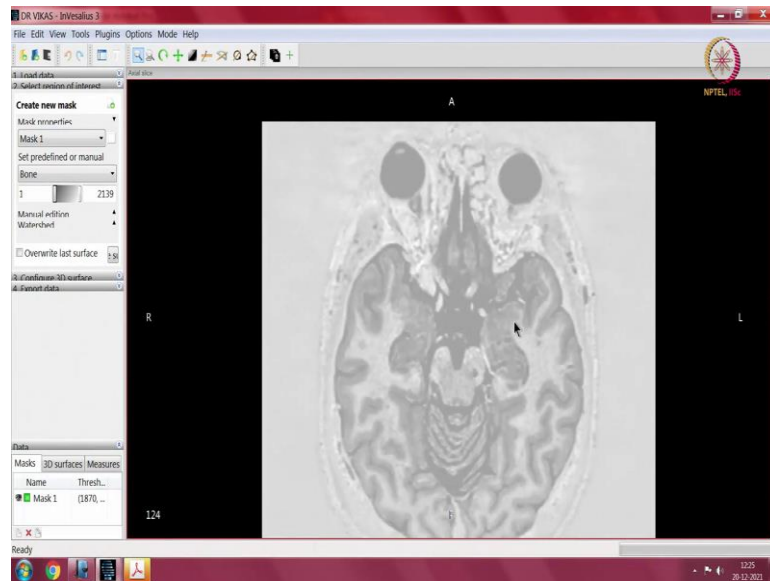
We would be seeing the corpus callosum. So, in an axial section you would see the corpus callosum both in front and somewhere in behind.

(Refer Slide Time: 27:50)



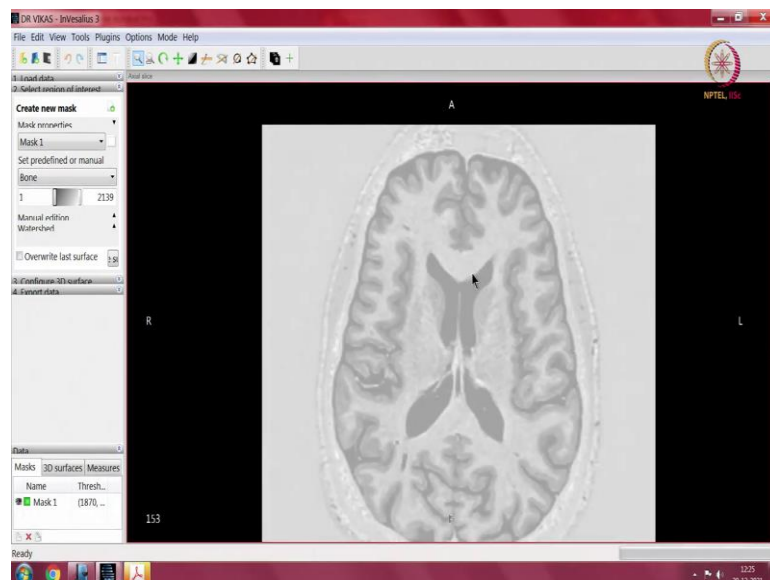
So, this is the splenium of the corpus callosum, this would be the genome of the corpus callosum.

(Refer Slide Time: 28:02)



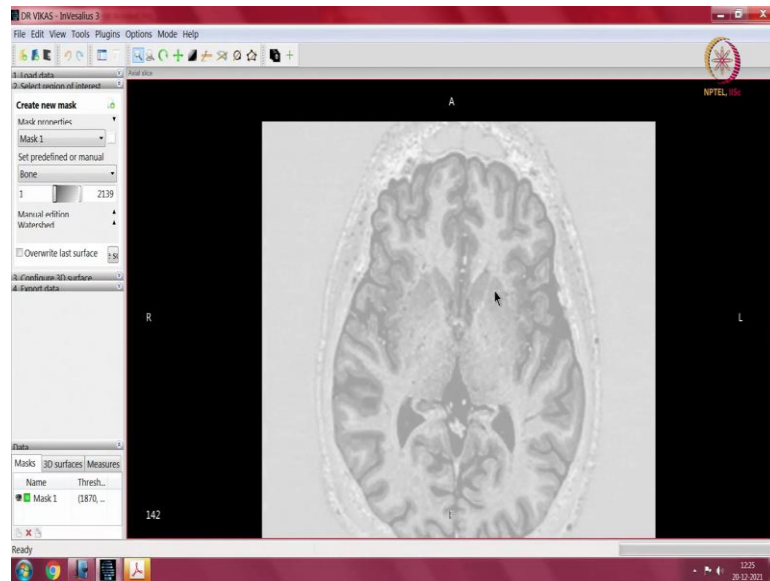
So, that is about what all we can see internal structure and the other anatomy we would go in the next phase. So, these are structures which are seen on the axial images of the brain.

(Refer Slide Time: 28:17)



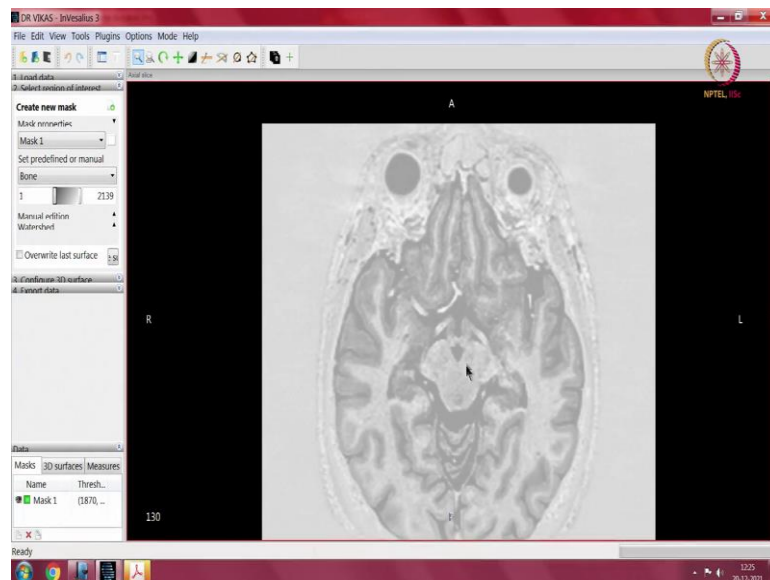
So, what would these be? Empty spaces within the brain are the ventricles.

(Refer Slide Time: 28:25)



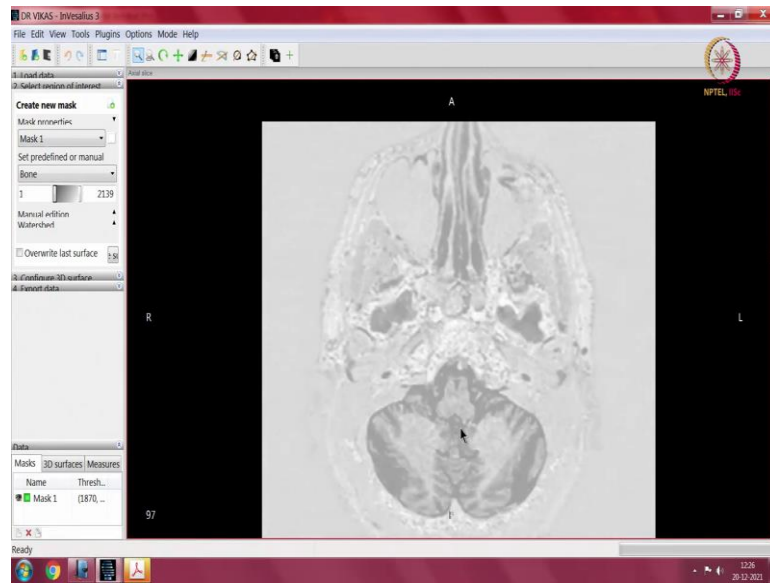
So, ventricles, that was the lateral ventricle here, which is in the cerebral hemisphere. The small place here in the center is the third ventricle.

(Refer Slide Time: 28:45)



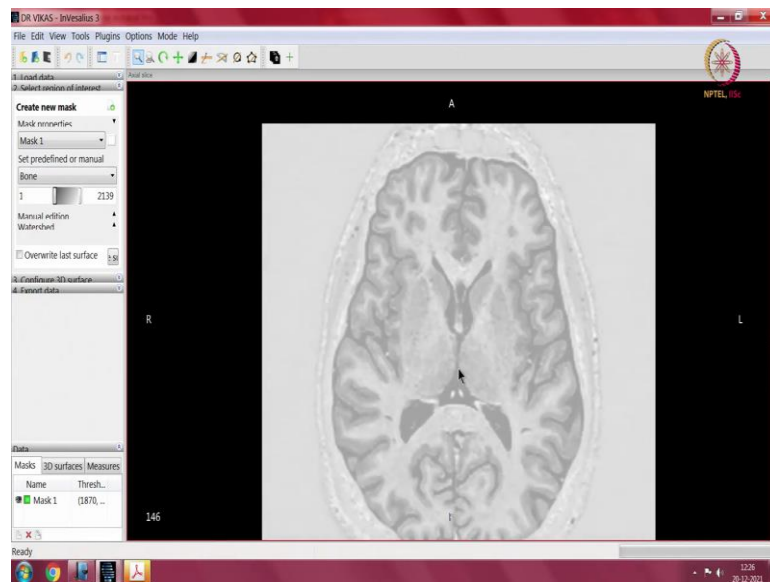
So, the third ventricle actually goes down into the midbrain, which is here, midbrain is starting over here. And this would be the aqueduct, the aqueduct opens into the fourth ventricle.

(Refer Slide Time: 28:59)



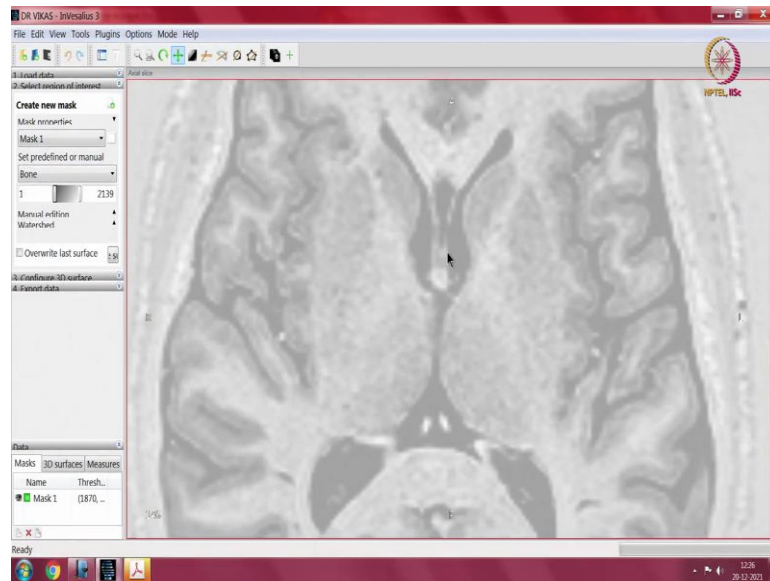
So, lateral third and fourth ventricle. So, that is the nomenclature communications are there between each of these ventricles and that is what you would need to remember ok.

(Refer Slide Time: 29:19)



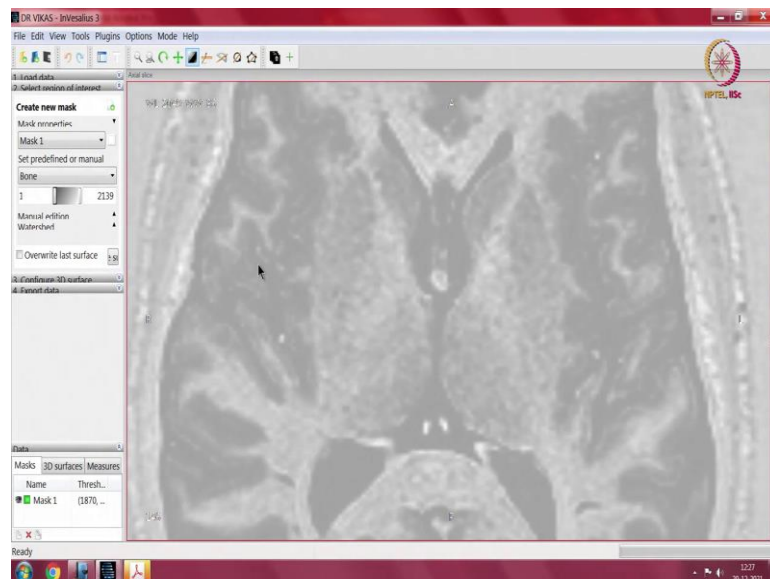
So, for the next part of the story is the deep gray.

(Refer Slide Time: 29:35)



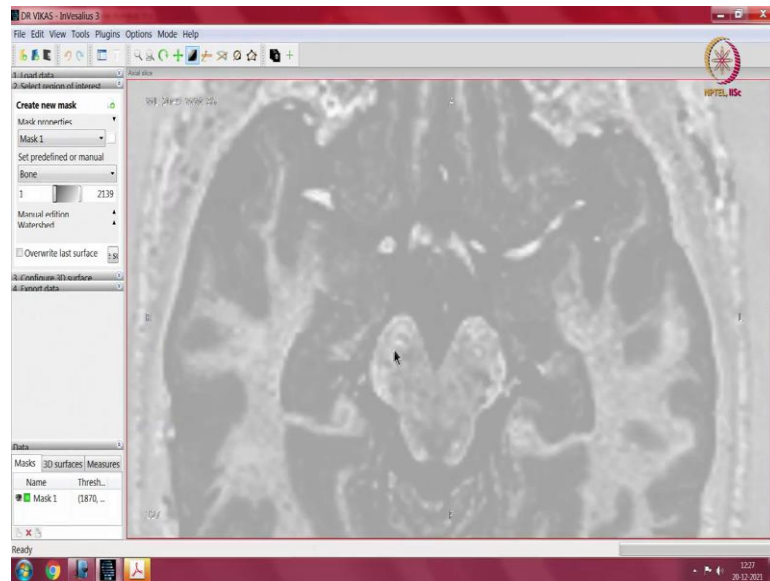
So, deep gray is I had highlighted that this is the.

(Refer Slide Time: 29:52)



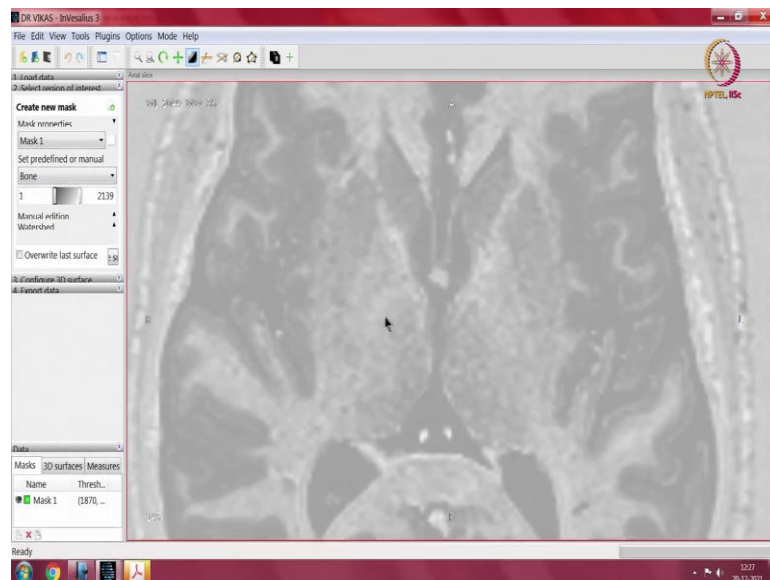
So, deep gray is present within the center of the brain. So, center of the brain its closely related to the ventricles. To highlight the deep structures I think I need to change the windowing a little more. So, right the first structure which I want to teach is about the thalamus, two thalami on either side. So, this is the egg like shape structure which is over here it is thalamus is almost in continuation with the midbrain.

(Refer Slide Time: 30:22)



So, when you come up, this is the midbrain, shape is very obvious, two cerebral peduncles aqueduct behind.

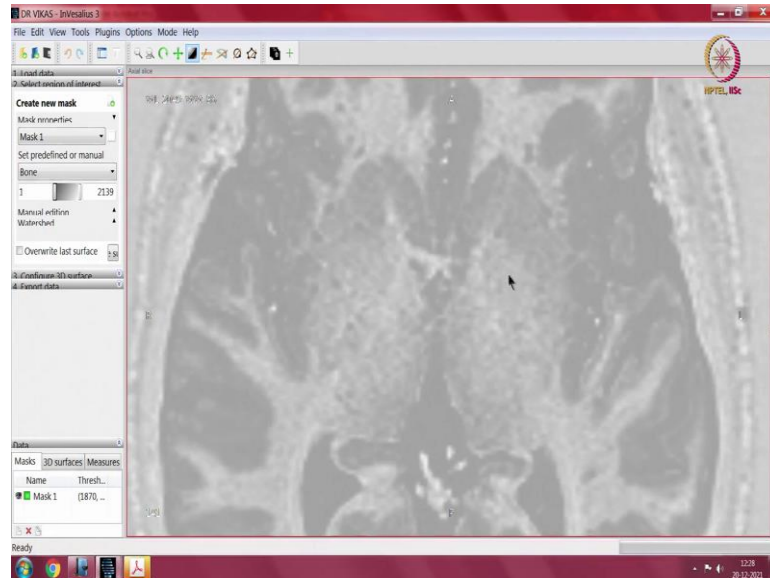
(Refer Slide Time: 30:33)



When the cerebral peduncles come up you would find the thalamus, it's obvious over here. So, you can find out some structure here darkish. So, this is white matter this is gray matter. So, that is the differentiation. So, white and gray. This is the thalamus in here. This bulge which is coming into the ventricle is the caudate head. So, thalamus,

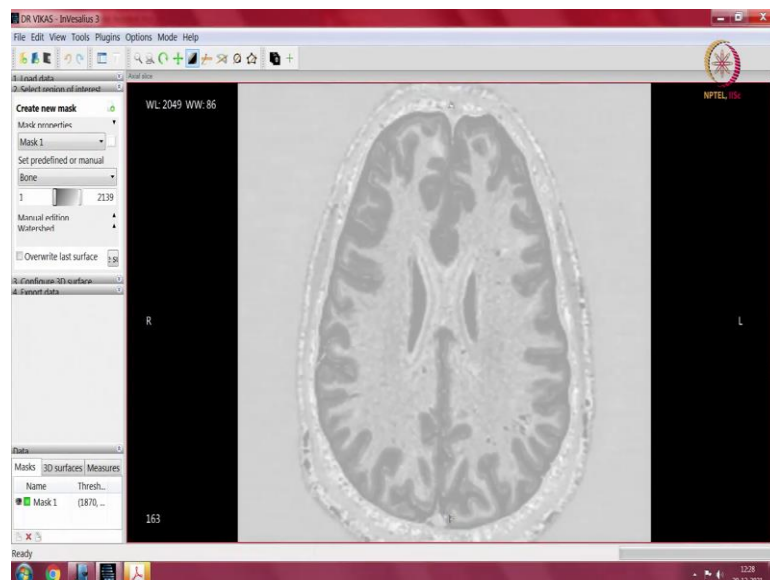
caudate head and the remaining structure is the lentiform nucleus with the globus pallidus which is inside.

(Refer Slide Time: 31:08)



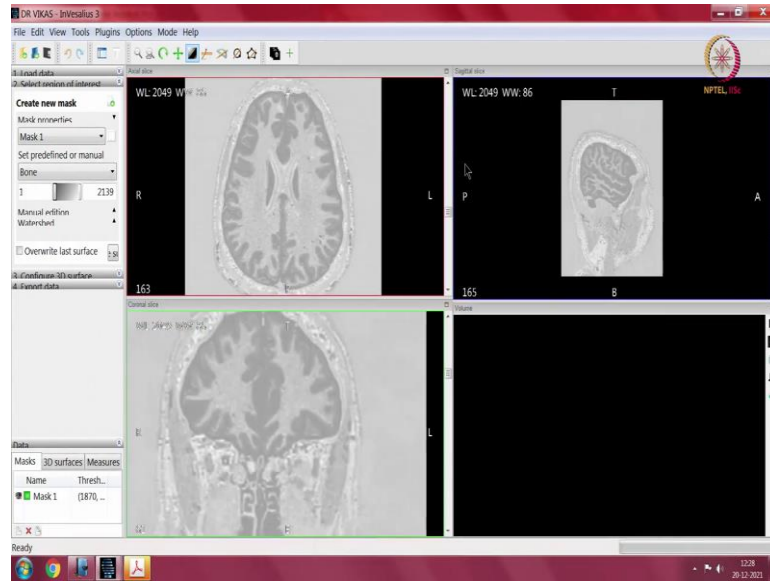So, that constitutes the deep gray and that also sort of completes the discussion in the axial section.

(Refer Slide Time: 31:22)



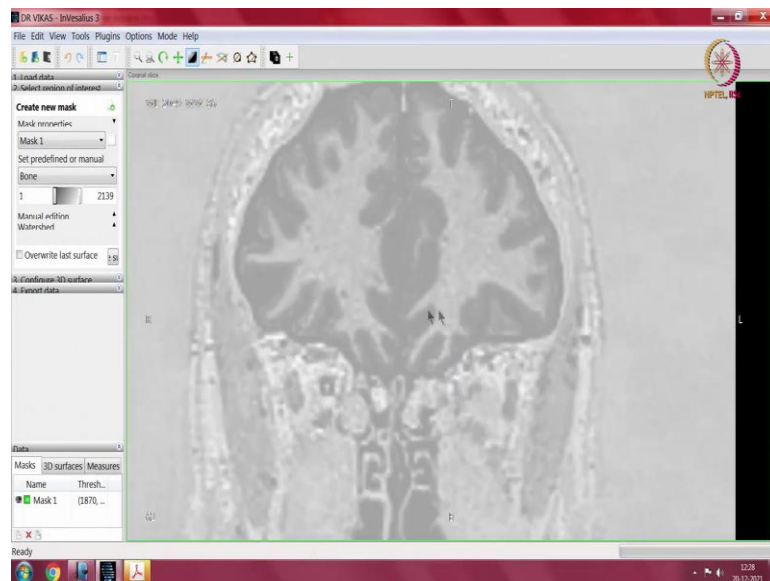


(Refer Slide Time: 31:28)



Let us see how these things look in various other sections.

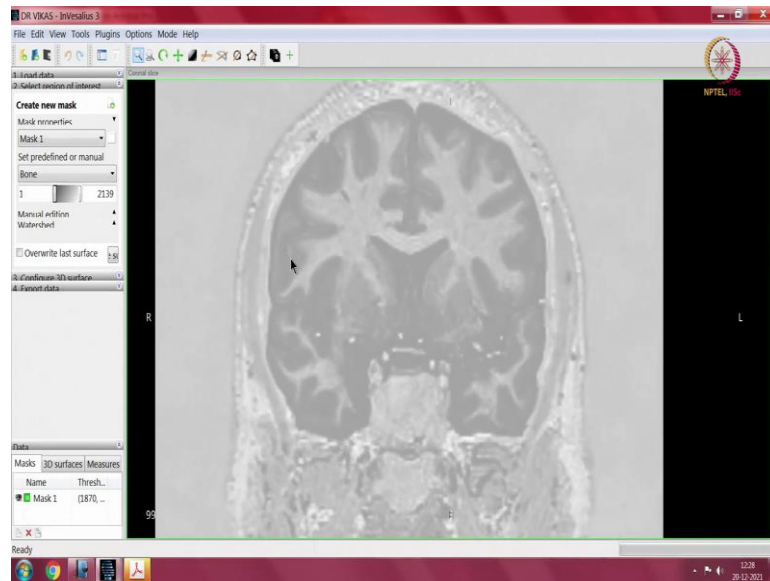(Refer Slide Time: 31:33)



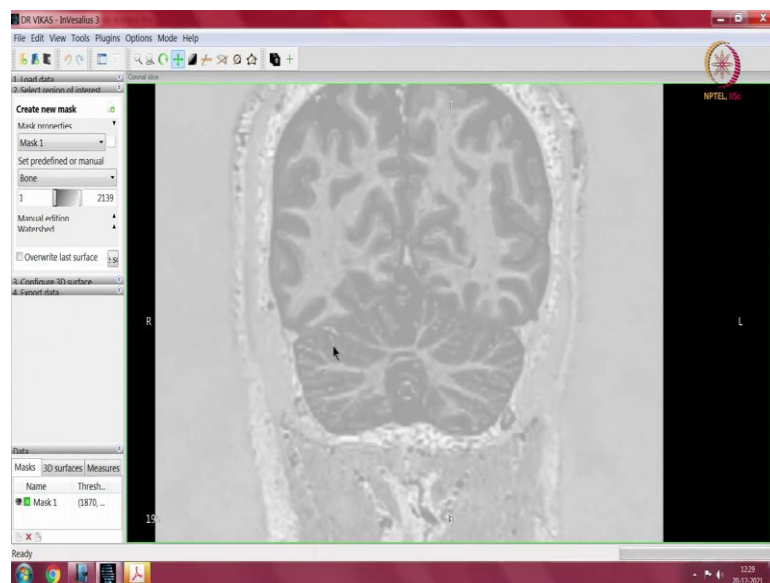
So, once the axial section is understood we proceed on to the coronal section.



(Refer Slide Time: 31:43)



(Refer Slide Time: 31:48)



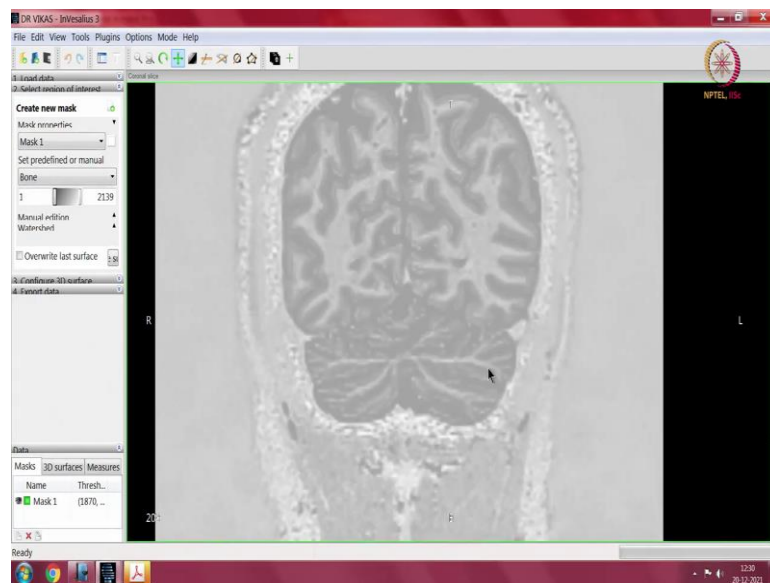
So, coronal section, since we started from behind we go back. This is front to back. So, this is the tentorium. So, tentorium separates the cerebrum from the cerebellum and the brainstem of course. So, the boundary is obvious, it's not obvious on imaging. So, please this is one of the fallacies with current imaging.

Though there is good resolution it is nowhere near actuals, and it is with actuals that we deal when you are actually treating patients and people. So, there is lot of gaps between what is seen on imaging and what is actually present. And these are not mythical

structures nicely seen, but unfortunately on imaging with even a 0.6 mm resolution we are not able to differentiate these things.

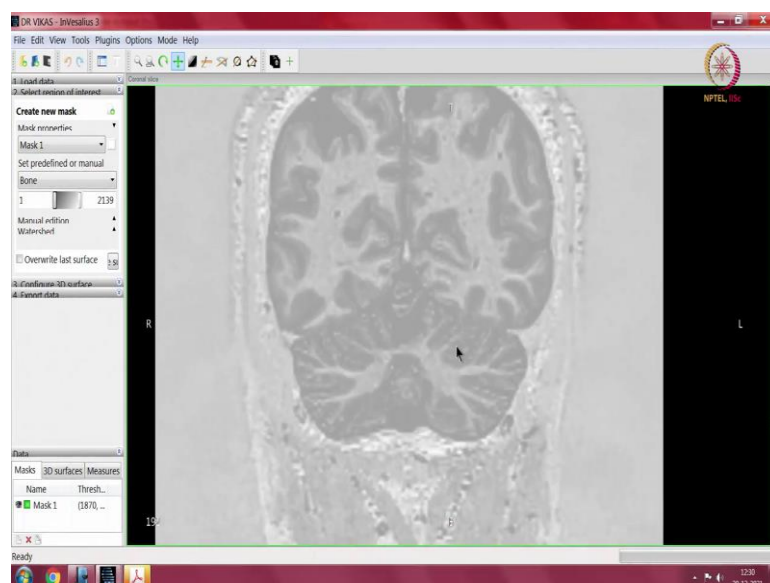
It will almost look like there is no boundary between the cerebrum and the cerebellum. So, here again we start from this, we are going from back to front ok. So, I have shown you I did not describe anything in from back to front.

(Refer Slide Time: 33:01)



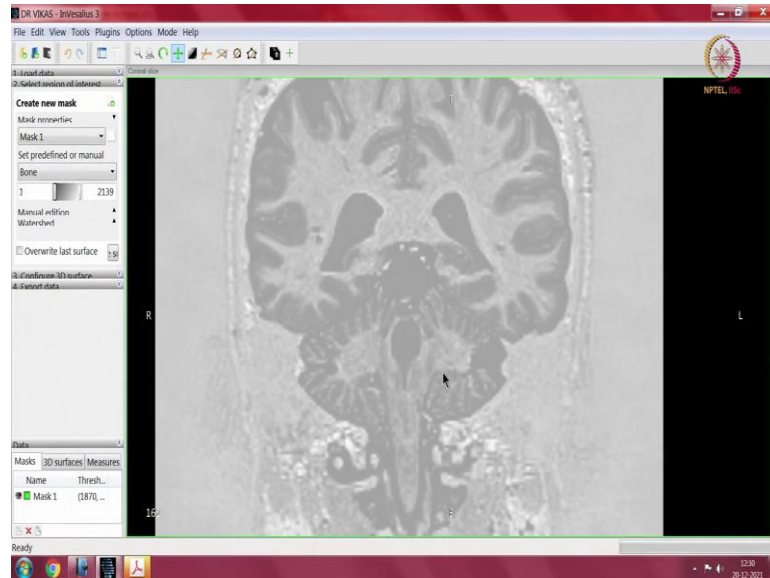
So, this is the left cerebellar hemisphere. Each of these front-like structures you can make out that its looking like leaves of a tree. So, each of this is the cerebellar folia.

(Refer Slide Time: 33:16)



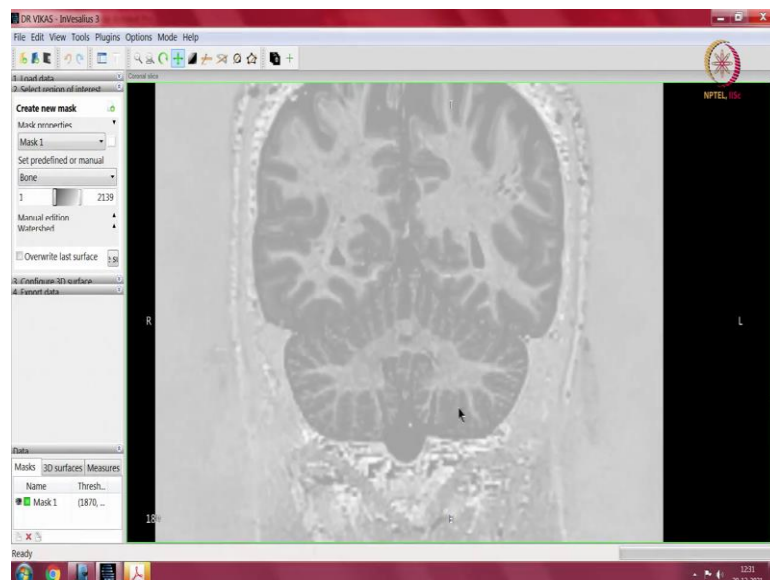
So, the foliar architecture is very nicely seen, and you can make out this foliar architecture over here.

(Refer Slide Time: 33:24)



Somewhere anterior would be there is a gray area over here and a gray area over here. So, those are the deep nuclei of the cerebellum.

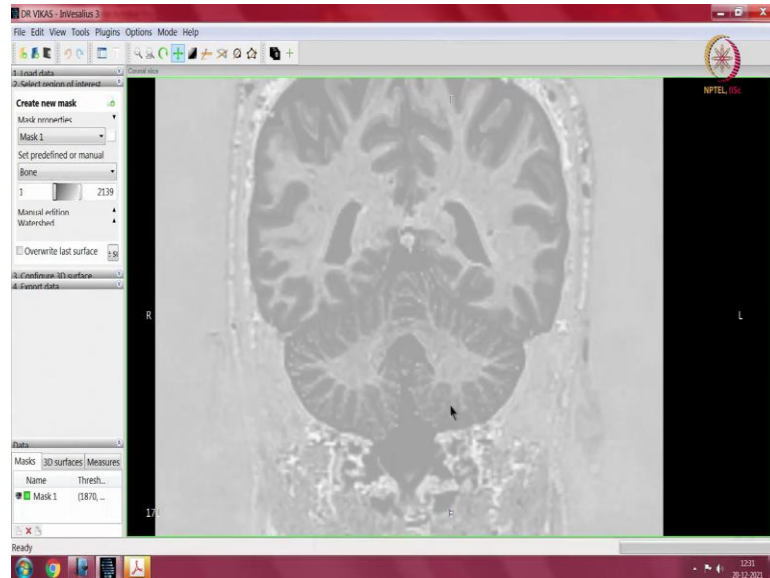
(Refer Slide Time: 33:39)



So, cerebellar cortex, this whole thing is cerebellar cortex. White matter of the cerebellum, white matter of the cerebellum, white matter of the cerebellum. So, this

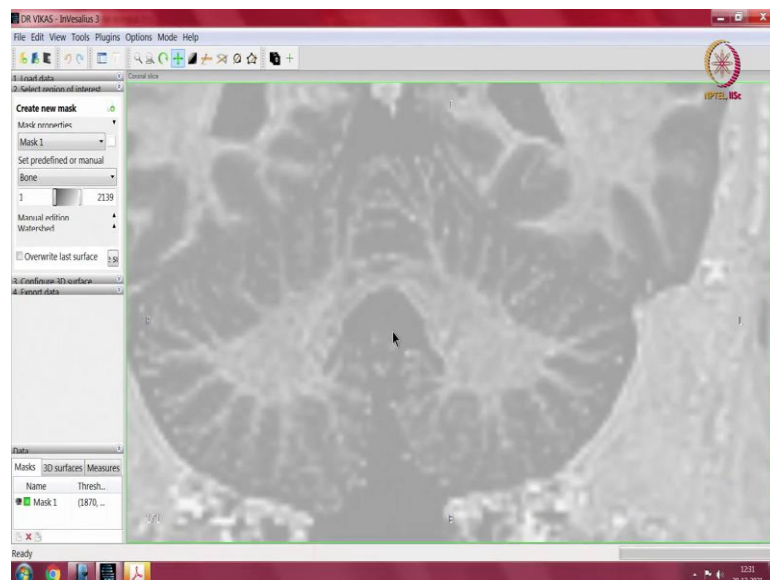
whole thing is the cerebellar cortex. Remember that this is a coronal section of the brain.

(Refer Slide Time: 33:57)



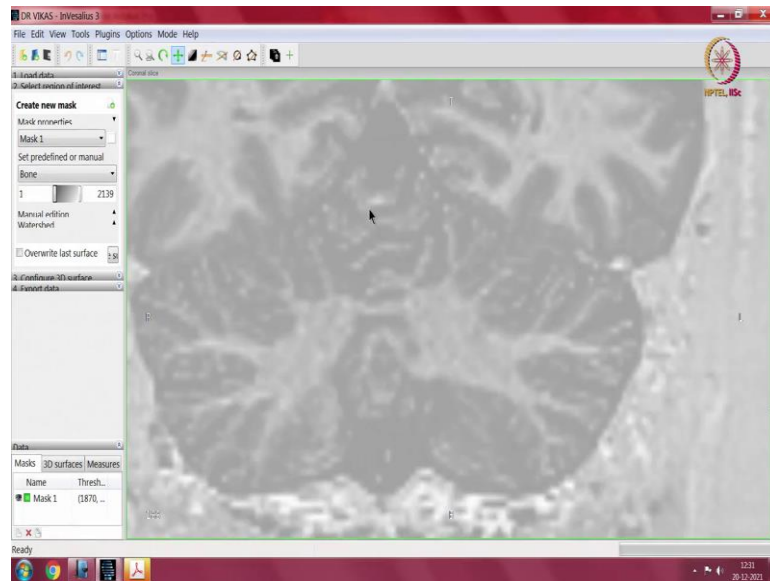
So, coronal section of the brain with this structure. So, this thing over here you can make out is the uvula it is seen differently on this kind of on the coronal section.

(Refer Slide Time: 34:09)



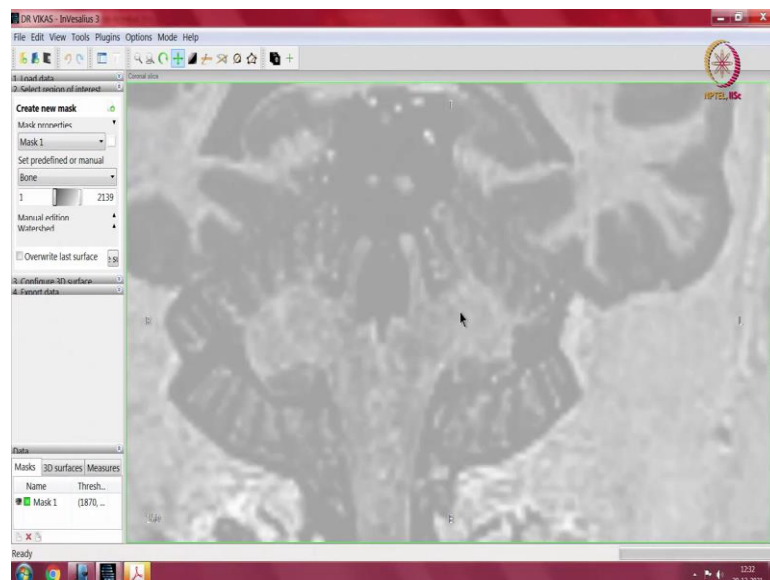
Uvula is the center is the side structures and this is the tonsil. So, tonsil continues into the vermis. So, how do I show the vermis?

(Refer Slide Time: 34:28)



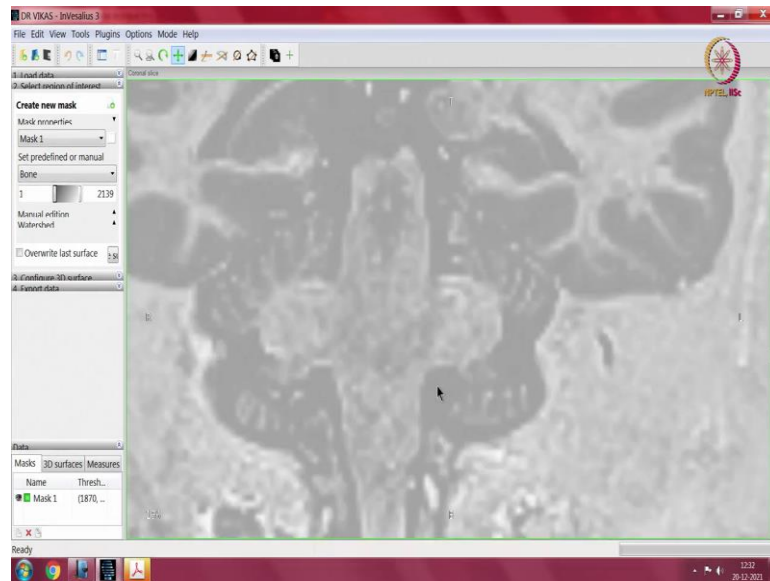
Yeah so, these things are the vermis this. It's quite different from the hemispheric structures which is there which is white matter in the center and gray matter in the periphery with the cerebellar folia.

(Refer Slide Time: 34:45)

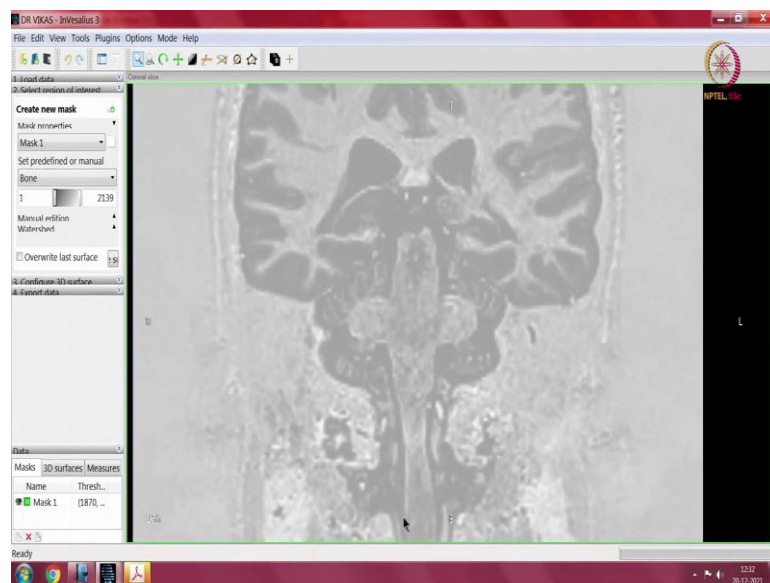


So, cerebellar hemispheres then this is the connection.

(Refer Slide Time: 34:49)



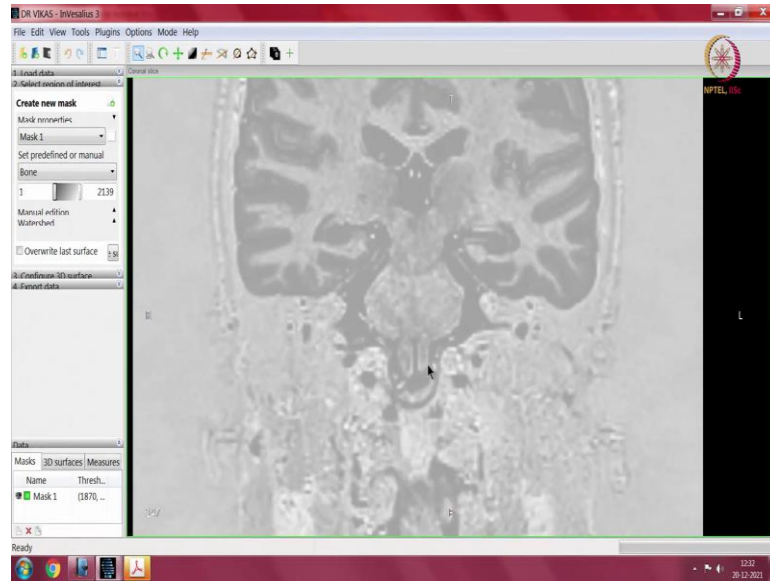
(Refer Slide Time: 35:06)



So, this is the brainstem. Connections to the brainstem, these white structures are connections to the brainstem. The central thing is the brainstem as such. I will reduce zoom. Spinal cord, medulla, there is this bulge which is coming over here which is the pons and upper part is the midbrain not very obvious as it was in the axial sections, but it is there.

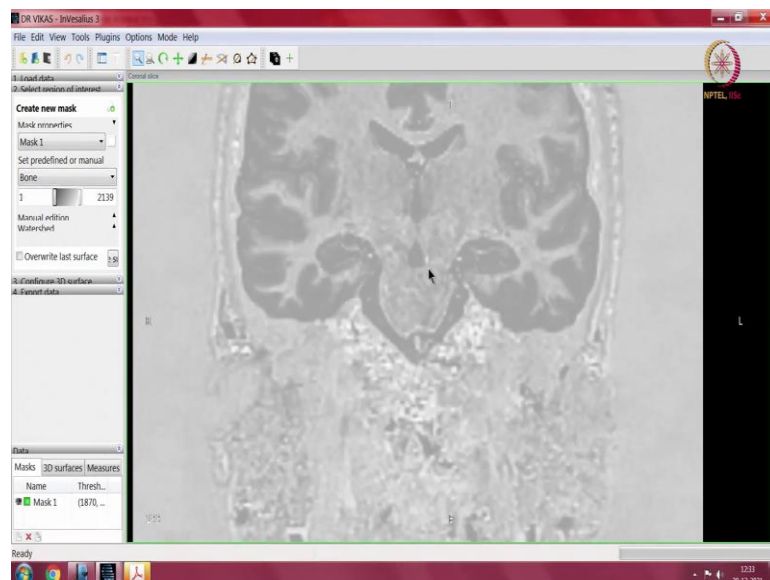


(Refer Slide Time: 35:24)



So, you can make out the size discrepancy between the two which I try to highlight in my 3D model. So, this is the medulla, the bulge of the pons and the midbrain which is somewhat bigger than the medulla.

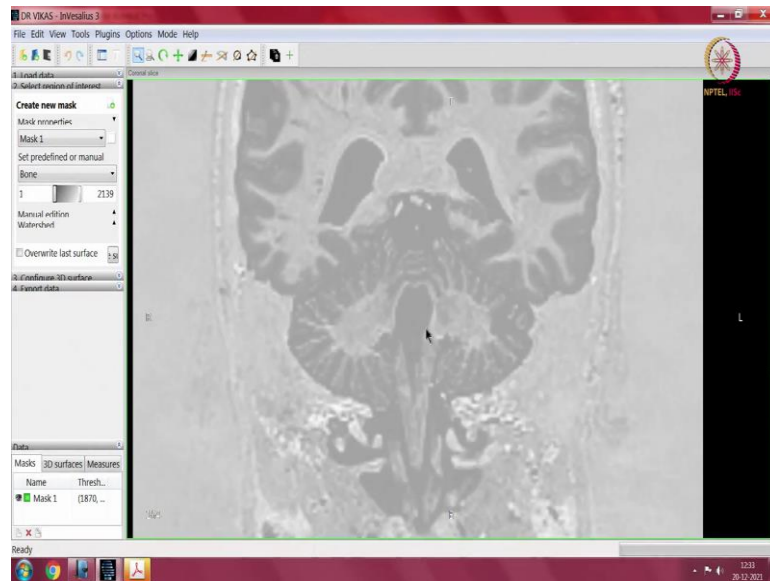
(Refer Slide Time: 35:43)



So, when we come anterior to that, this would be the aqueduct, third ventricle and lateral ventricle. So, we see a lot of structures, this is the lateral ventricle again cut section please remember this is the third ventricle and lower down is the aqueduct which is connecting with the fourth ventricle.

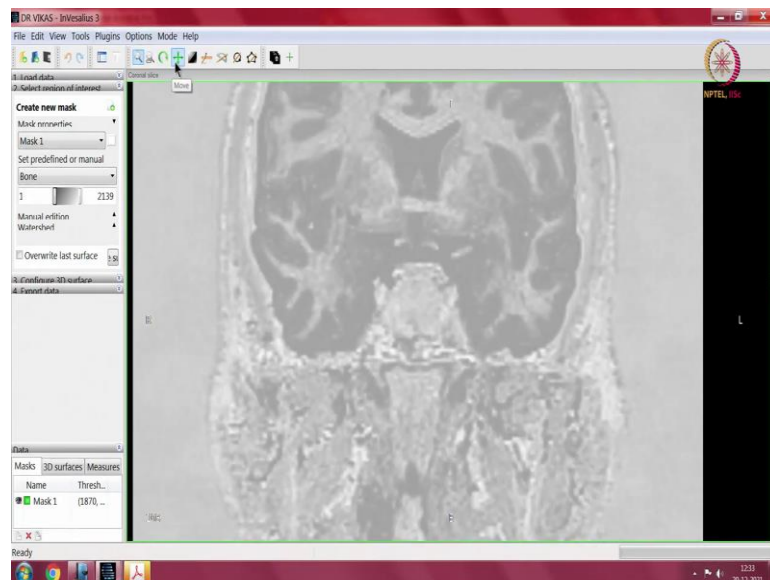


(Refer Slide Time: 36:06)



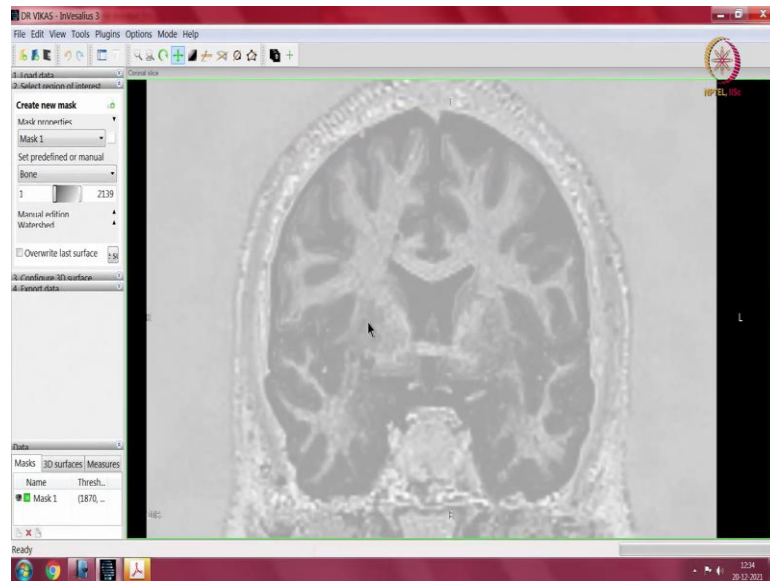
So, fourth ventricle is this black space. So, black space not very clear on the axial imaging, but here you can make out that it's a distinct cavity. And the very distinct cavity continues up to the aqueduct. So, the aqueduct and then continues into the third ventricle.

(Refer Slide Time: 36:24)



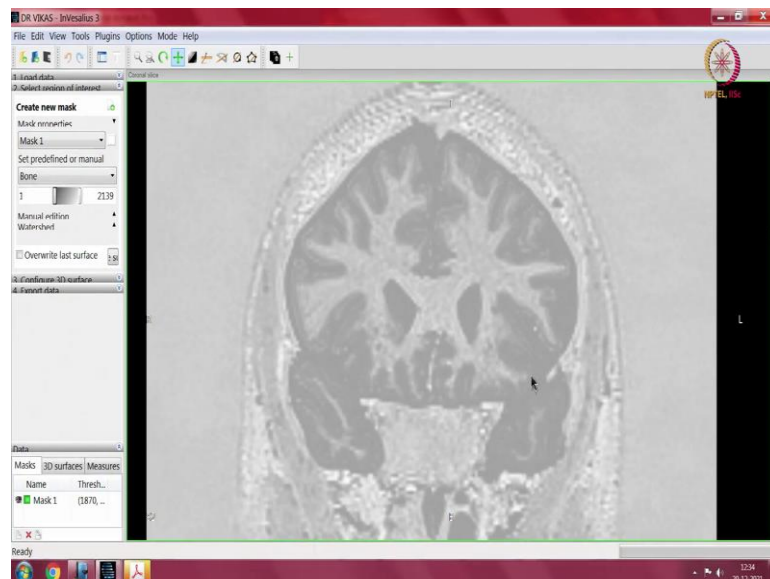And then through the third ventricle it goes into the lateral ventricle.

(Refer Slide Time: 36:33)



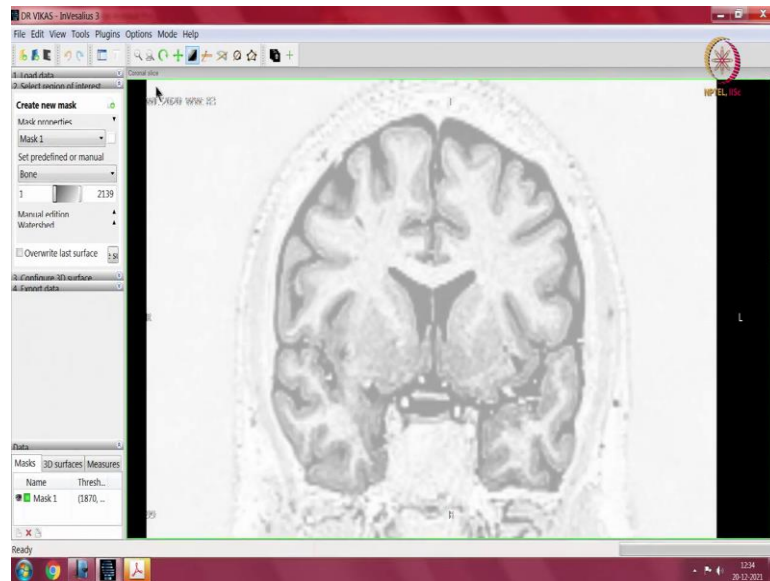
So, we go further up cerebrum.

(Refer Slide Time: 36:38)



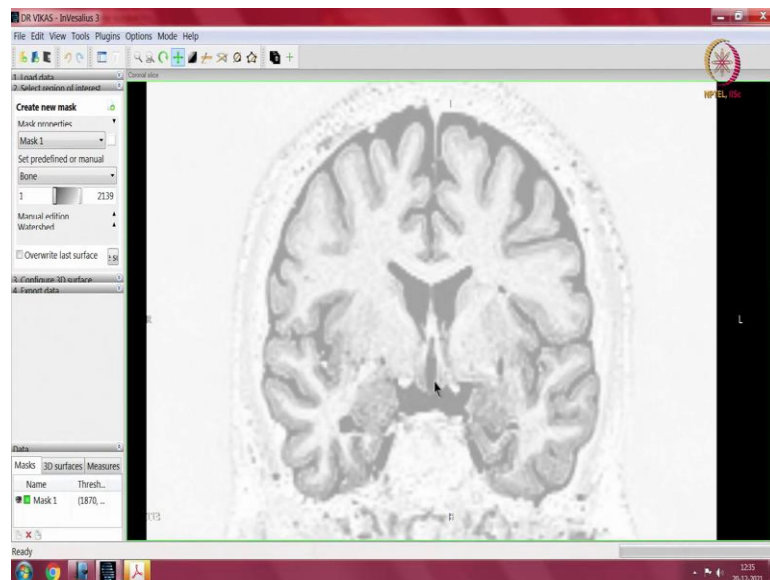
So, front you can make out this distinct separation between the frontal lobe and this is the temporal lobe. So, temporal lobe downwards, frontal lobe upwards and there is the sylvian fissure which is over here. So, that is how it gets differentiated, not very clear here is the insula which I think I should showcase yeah.

(Refer Slide Time: 37:02)



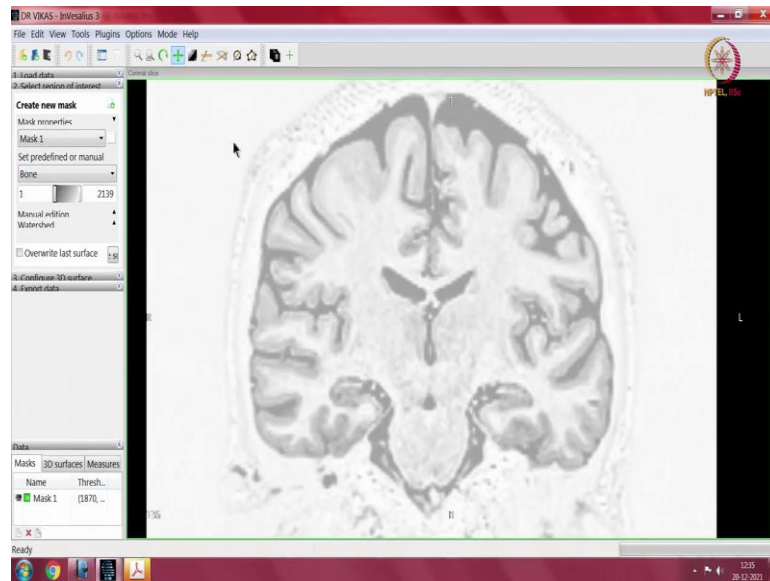
So, this is a better delineation of the insula yeah. So, within the deeper parts of the brain. So, the deeper parts of the brain are this structure this is the insular cortex.

(Refer Slide Time: 37:25)

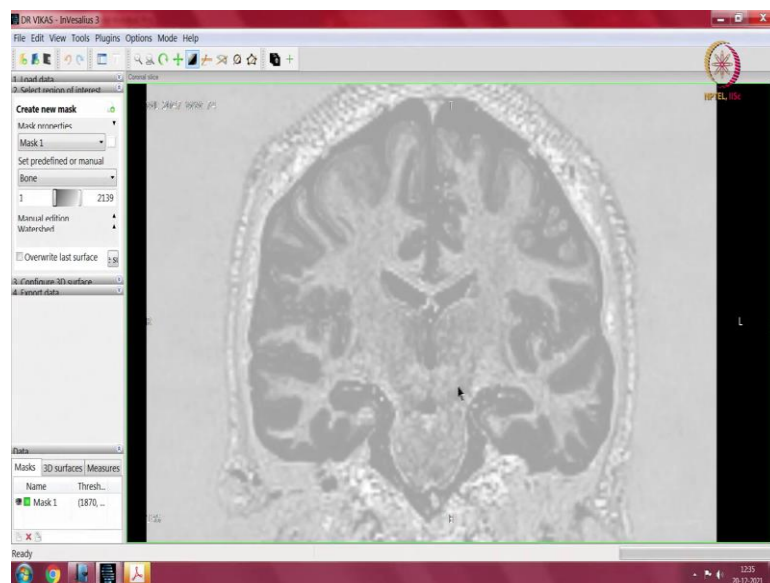


Temporal lobe, frontal lobe and posteriorly this is the parietal lobe, temporal lobe, insula. So, that is how it is. So, this space here is the sylvian fissure this is the insula, insula and this would form the ventricles lateral ventricles, this forms the third ventricle. Now, so we spoke about thalamus in the axial section let us try if we can get that in the coronal sections.

(Refer Slide Time: 38:01)

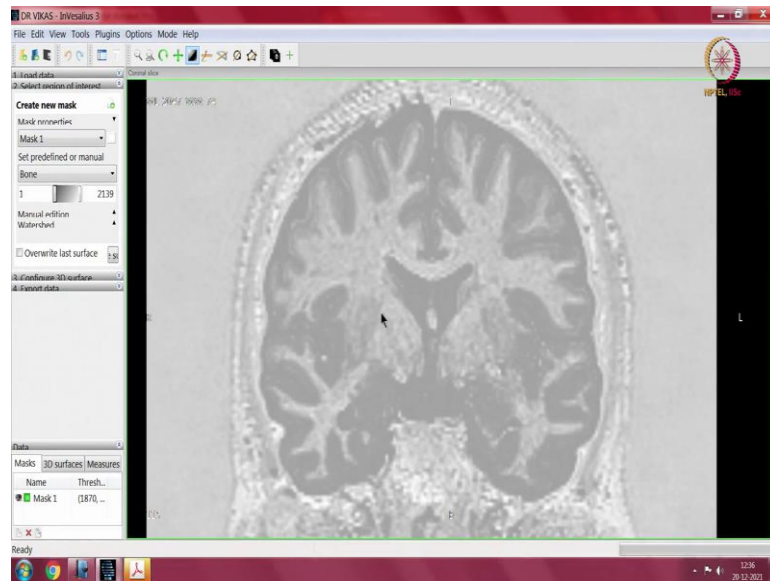


(Refer Slide Time: 38:09)



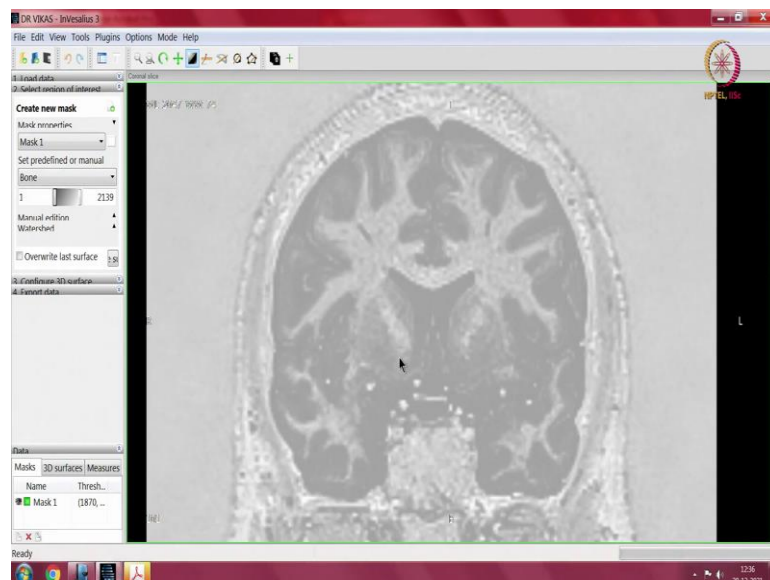
So, we go back, change the window to appreciate the gray matter better. So, this is the brainstem, this would be the midbrain area and then just above the midbrain area this round structure over here is the thalamus.

(Refer Slide Time: 38:33)



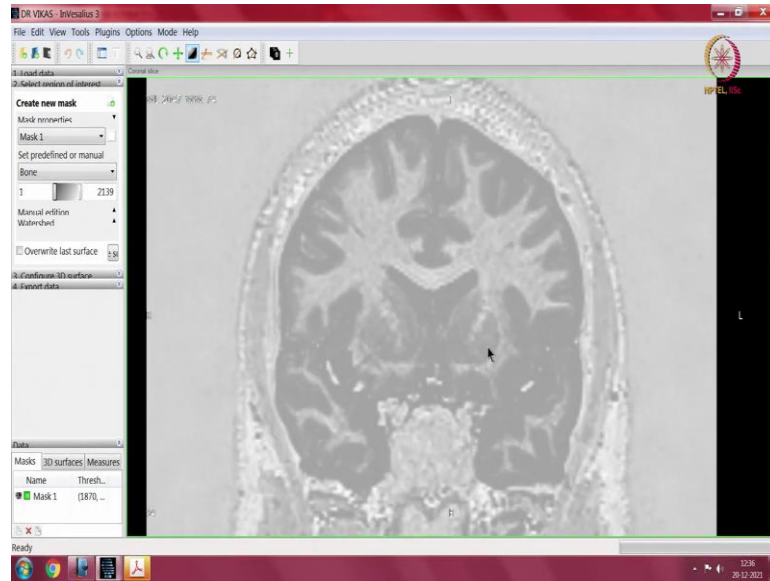
Come more front, thalamus is only a small part over here. This is the caudate head which projects into the ventricle, caudate head which projects into the ventricle, lentiform nucleus a bit clearer.

(Refer Slide Time: 38:54)



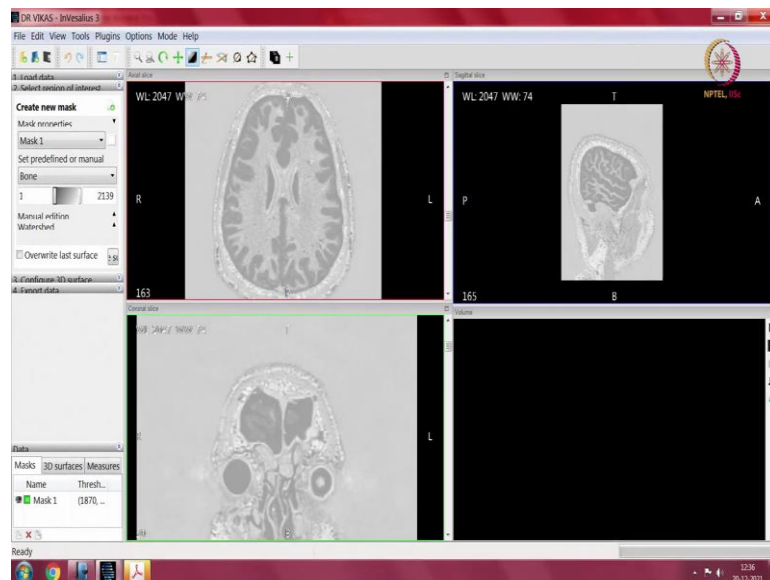And I think this anterior part is the globus pallidus over here, globus pallidus over here caudate head.

(Refer Slide Time: 39:02)



So, this is caudate head again and the lentiform nucleus. So, that sort of finishes the description in the coronal sections.

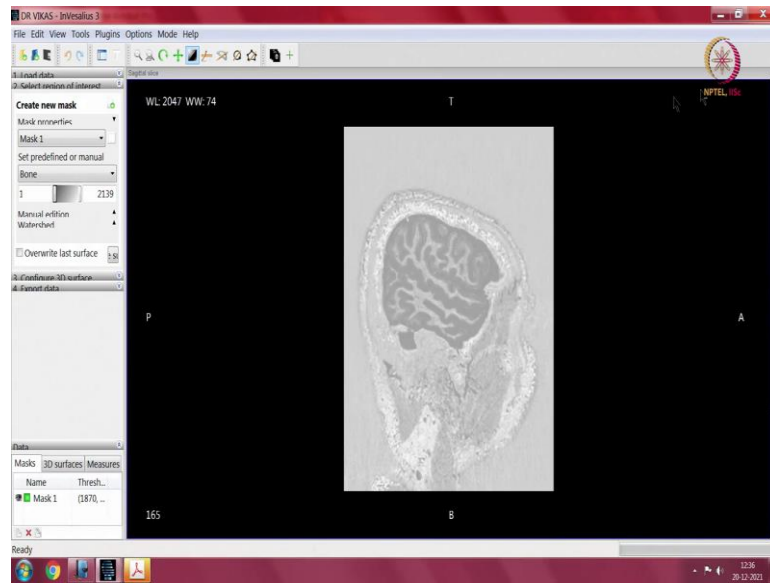
(Refer Slide Time: 39:18)



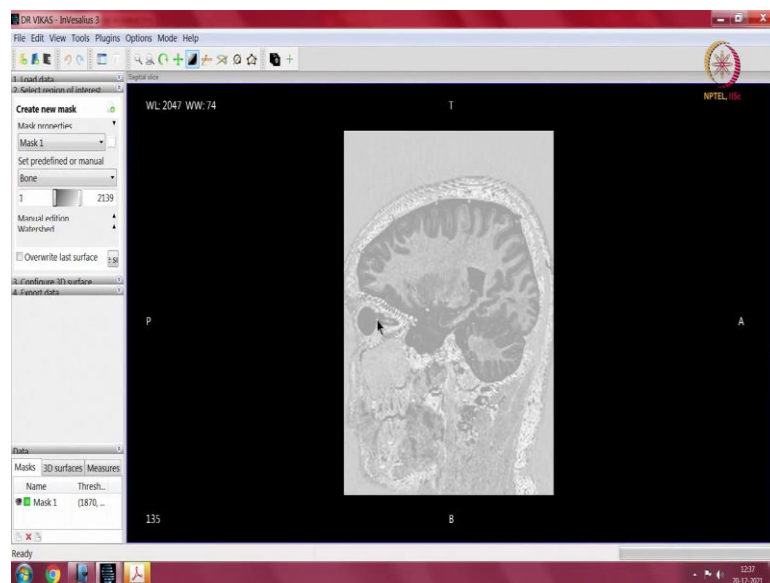
Sagittal sections, sagittal is from front to back ok.



(Refer Slide Time: 39:20)



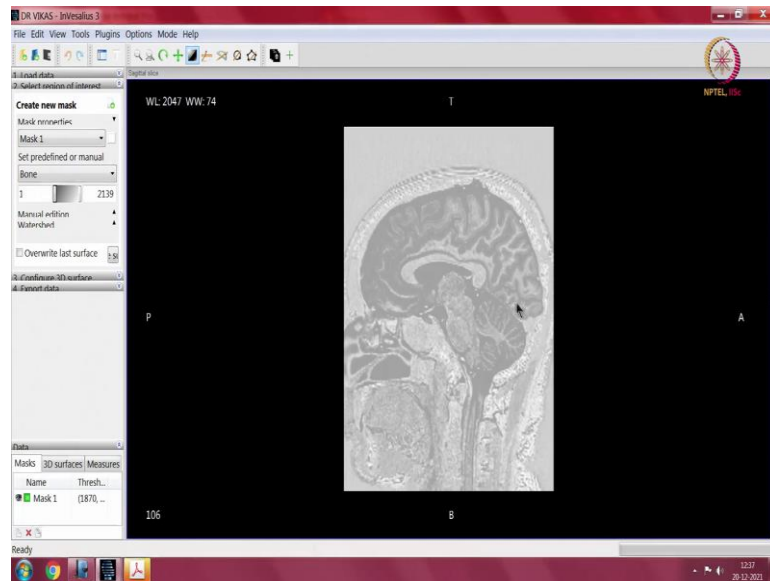
(Refer Slide Time: 39:26)



Again to make it clearer this is the eye one eye you can see a small structure which is coming out from the eye that is the optic nerve yeah.

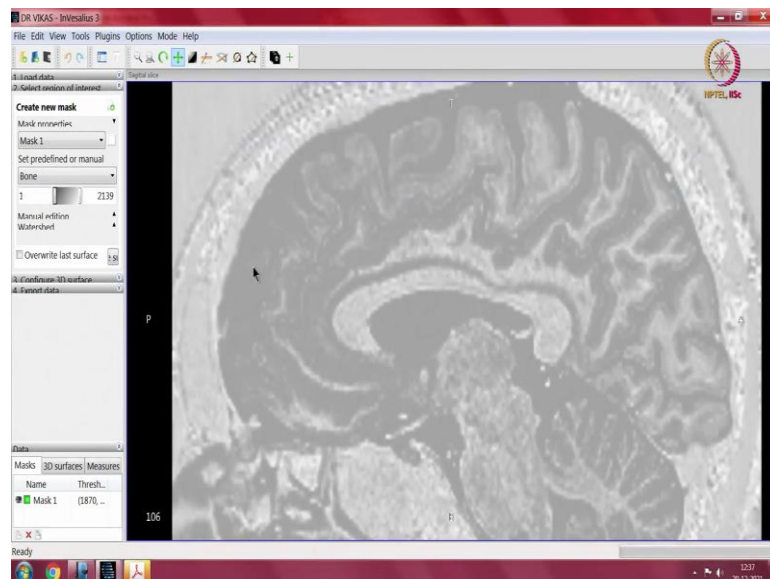


(Refer Slide Time: 39:43)



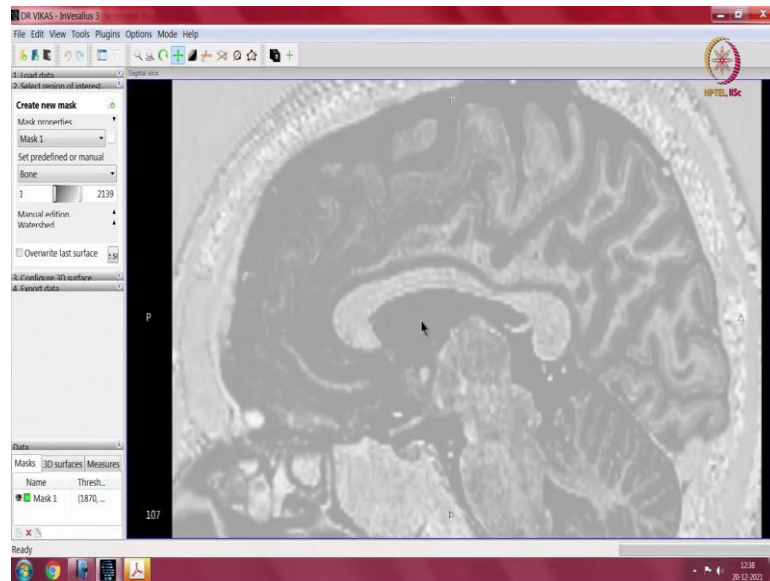
So, these are things which are to be appreciated over here.

(Refer Slide Time: 39:56)



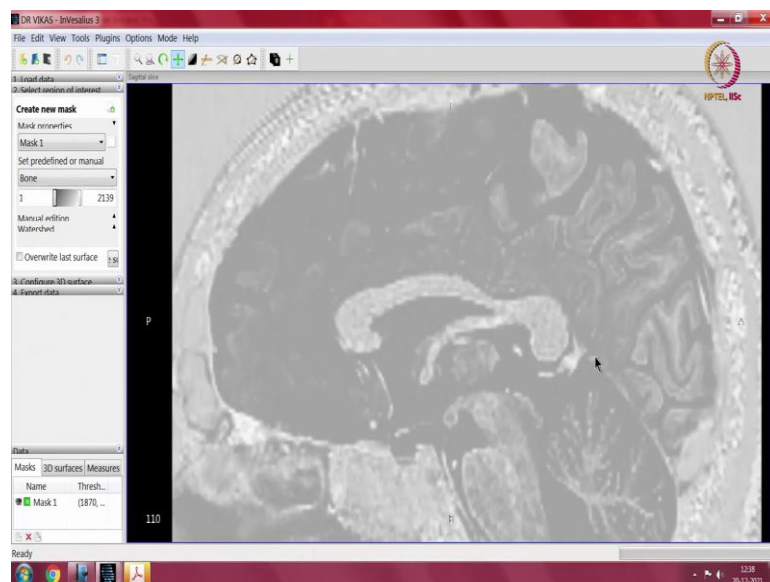
So, we have so far just discussed about the corpus callosum. So, here you can clearly see the corpus callosum, I will zoom it further. So, rostrum genu body and the splenium. So, that is how it looks like. This whole stuff is the corpus callosum. The corpus callosum connects between the two hemispheres as the biggest connecting fibers between the two hemispheres. We actually do not know much about the purpose of the corpus callosum.

(Refer Slide Time: 40:25)



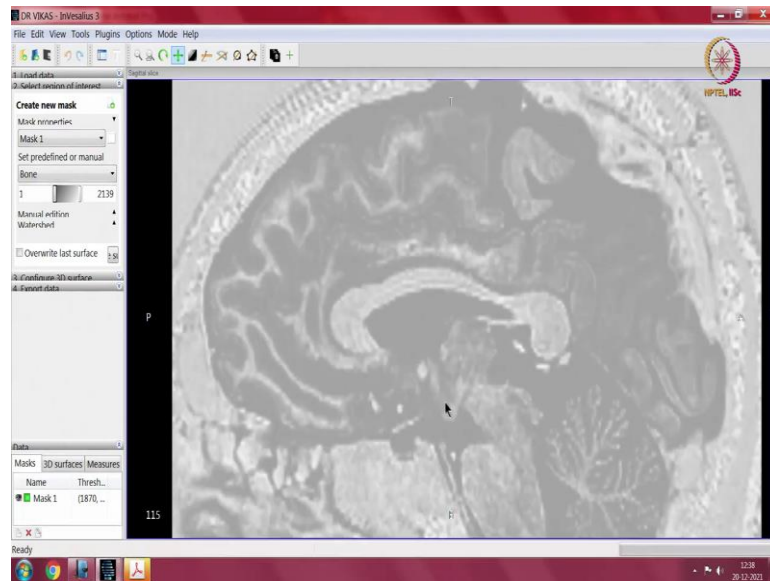
But operatively we know that if we can cut about two centimeters without causing any severe problem.

(Refer Slide Time: 40:33)



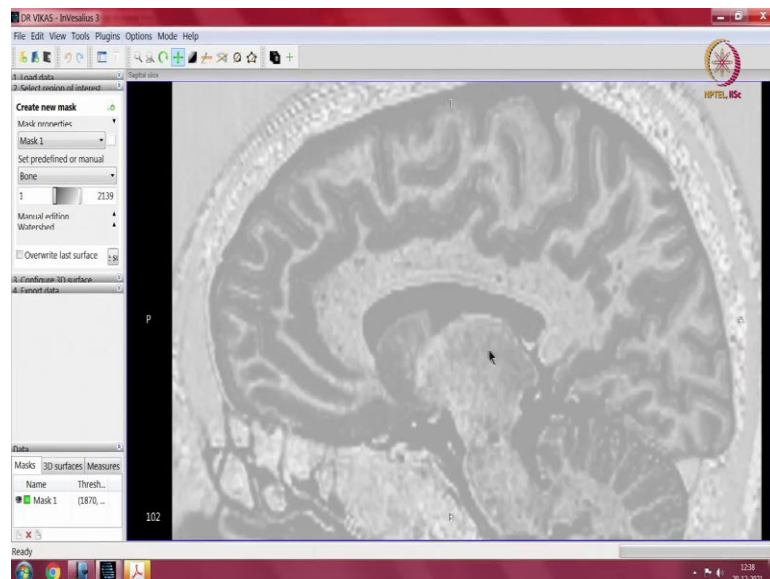
So, the corpus callosum communicates between two sides. Now in my 3D description I spoke about the fornix. So, this is the fornix over here, right underneath the corpus callosum and it is going from front to back and it goes to this thing called as the mamillary body. You cannot see it in a single structure, but a single section.

(Refer Slide Time: 40:55)



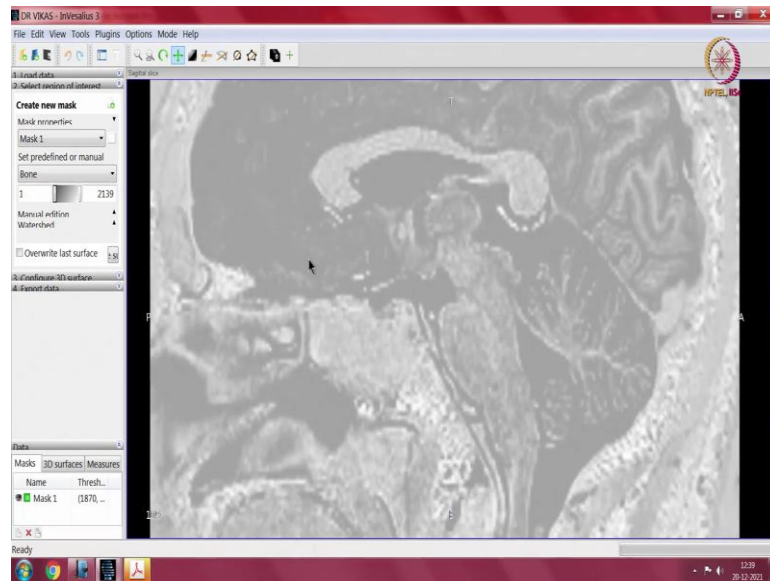
But you can see that it is this is the fornix.

(Refer Slide Time: 41:02)



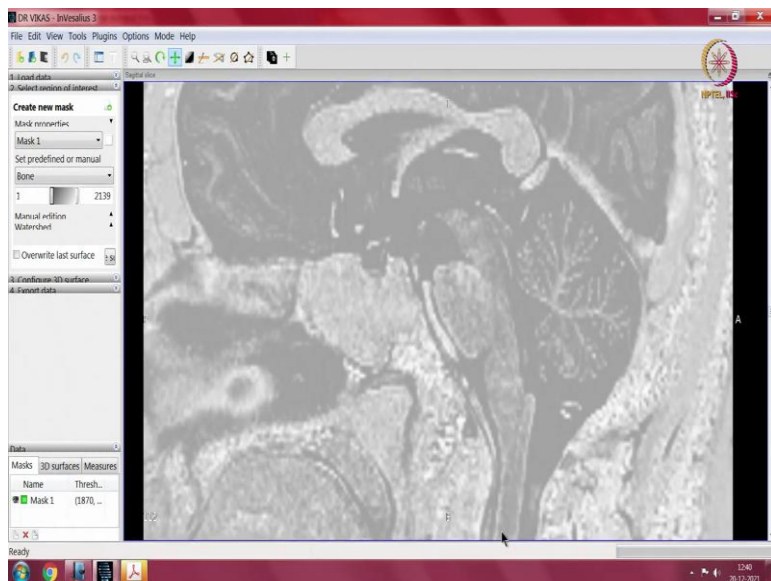
And then it goes around the thalamus. So, this is the thalamus, thalamus here brainstem here. So, this is the midbrain you can see the midbrain which is continuing almost with the thalamus. Just below the midbrain is the pons which you can again see as a bulge, a distinct bulge which is separate from which is separate from the midbrain.

(Refer Slide Time: 41:28)



So, following the midbrain sorry following the pons down you can see this pons.

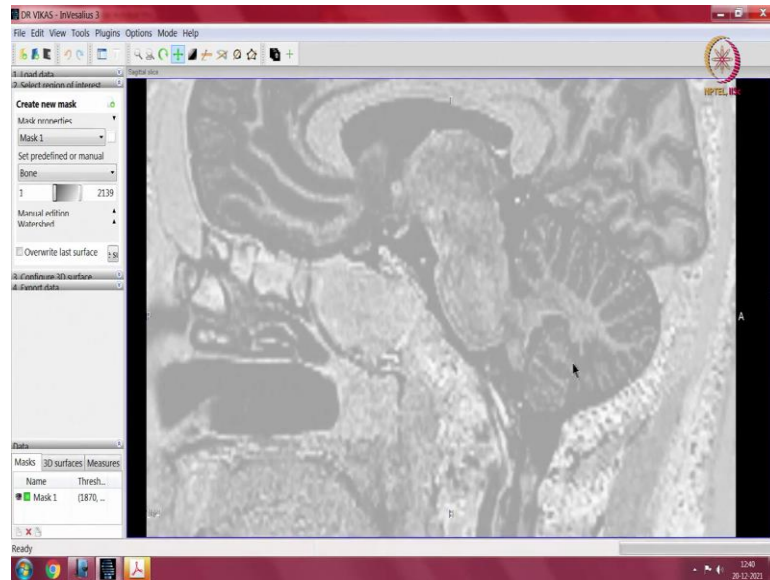
(Refer Slide Time: 41:32)



And there is another bulge over here. So, this is the pyramid of the medulla and the pons sense here, pyramid of the medulla. This part is the floor of the fourth ventricle. So, floor of the fourth ventricle I took some time to explain how it is rhomboid in structure. Then there is a roof of the fourth ventricle which is formed by the cerebellum.

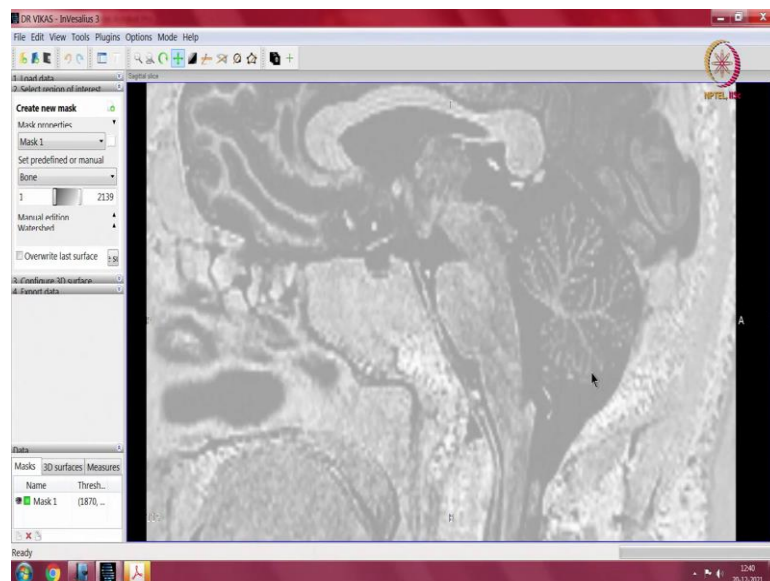
So, this is the v shaped roof of the fourth ventricle, this is the fourth ventricle. And this is the foramen of magendie; magendie in the midline. So, this is midline. So, many things in the midline, which we did not see in any of the other sections. So, this is corpus callosum, fornix, midbrain, pons, medulla with the pyramid and this is the spinal cord.

(Refer Slide Time: 42:27)



I go a bit outside that is lateral and you can see the uvula sorry this is the tonsil.

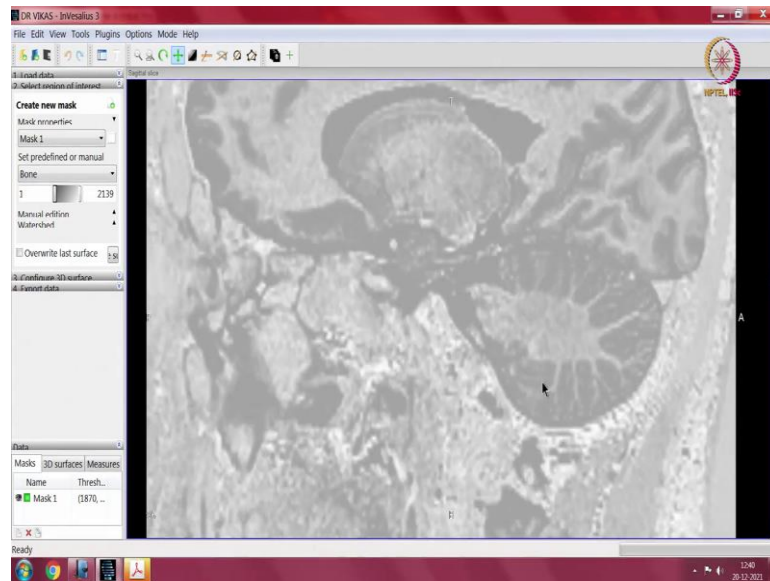
(Refer Slide Time: 42:50)



This would be this would be the uvula in the midline ok. And we go much more further only things which you see are the cerebellar hemispheres.

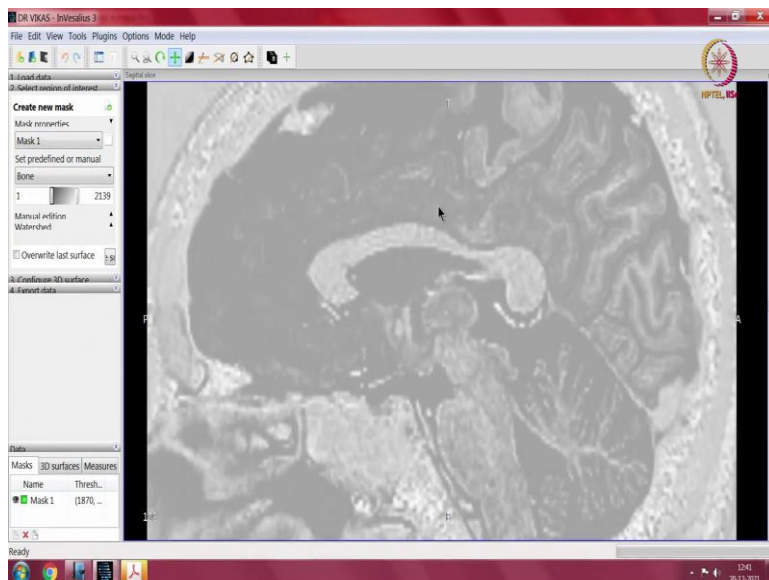


(Refer Slide Time: 43:00)



Cerebellar hemispheres you can see the white matter in the center, the white gray cortex in the periphery.

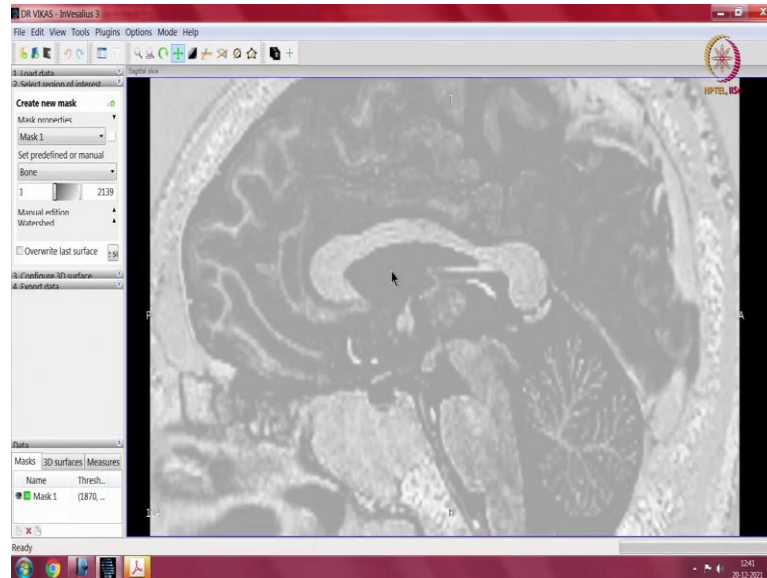
(Refer Slide Time: 43:18)



Coming up go back to the center. So, this is the center because you are seeing the corpus callosum as a distinct identical identity you do not see it in continuity with something else. So, this structure is the tentorium. So, the tentorium separates the supratentorium from the infratentorium, cerebrum from the cerebellum. And through the incisura which

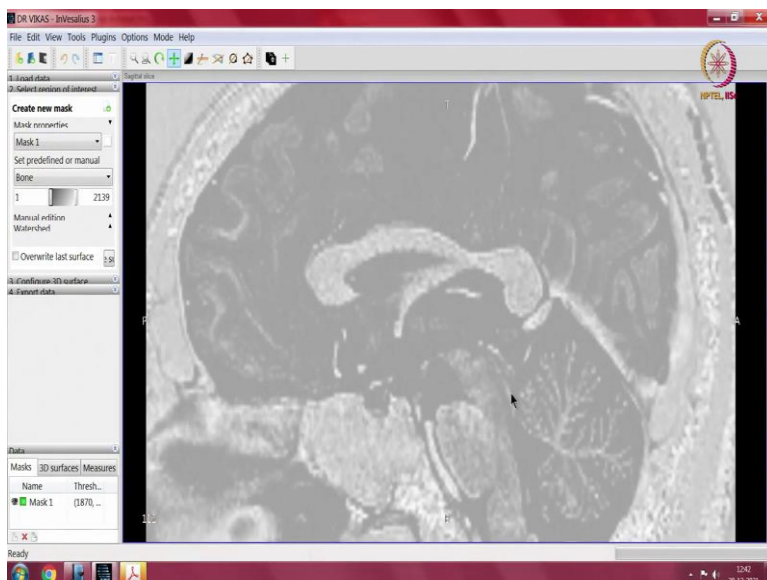
is the opening in the tentorium, the brainstem and other structures communicate with each other yeah.

(Refer Slide Time: 43:53)



So, once that is the splenium is understood what comes underneath is the lateral ventricle.

(Refer Slide Time: 44:05)



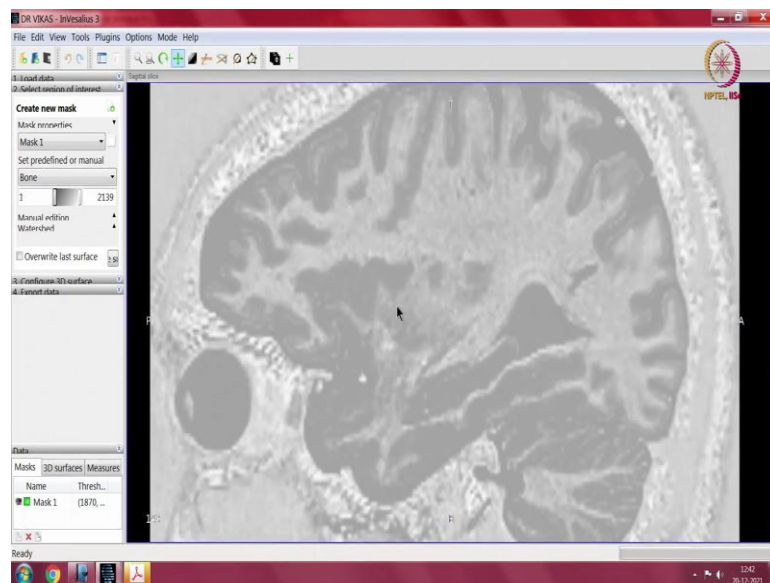
Then this is the region of the communication between the lateral ventricle and the third ventricle. Third ventricle is again in the midline. So, this black space over here is the



third ventricle, this is lateral ventricle. Communication through across the foramen of monro which is situated over here.

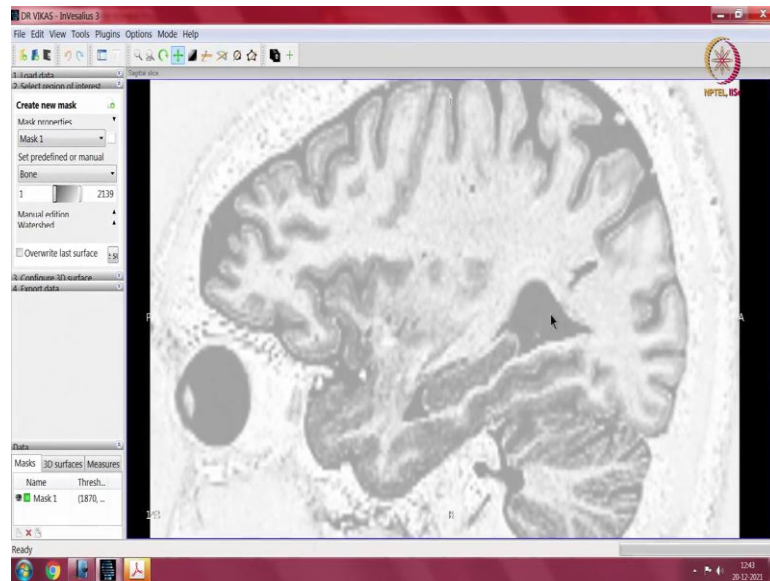
So, we will see if we can trace out the aqueduct over here. So, this is the aqueduct here central space communicating within third ventricle over here, this is the phonics. So, third ventricle here third ventricle. And through aqueduct into fourth ventricle over here. So, that is how it is arranged. Then we see if we can identify further structures difficult in this sagittal structure sagittal section.

(Refer Slide Time: 45:00)



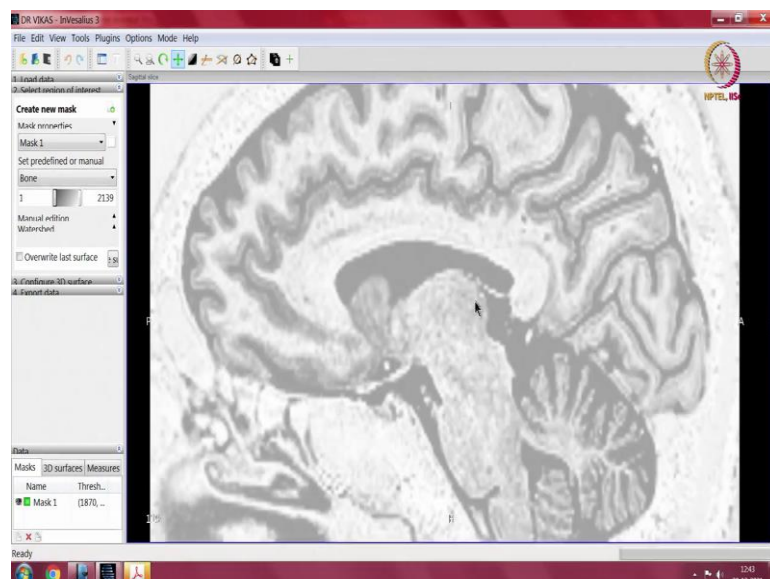
So, there is one structure which I think is very obvious we have which I should highlight.

(Refer Slide Time: 45:10)



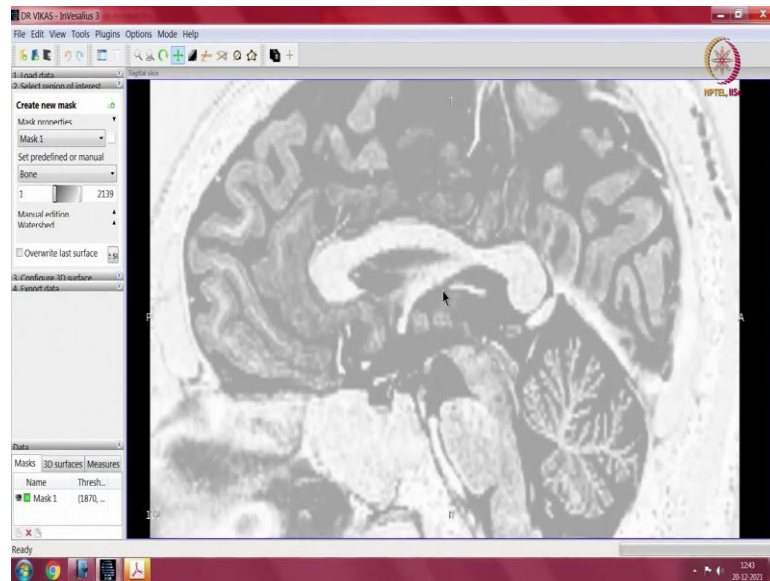
Yes so, you can see something over here. Now this is the temporal lobe. So, this is the frontal lobe, parietal lobe, occipital lobe, temporal lobe. In the temporal lobe is the continuity of the lateral ventricle and that is the horn and then this is the hippocampus. So, you can see one structure here which is projecting into the temporal horn and that is the hippocampus right.

(Refer Slide Time: 45:48)



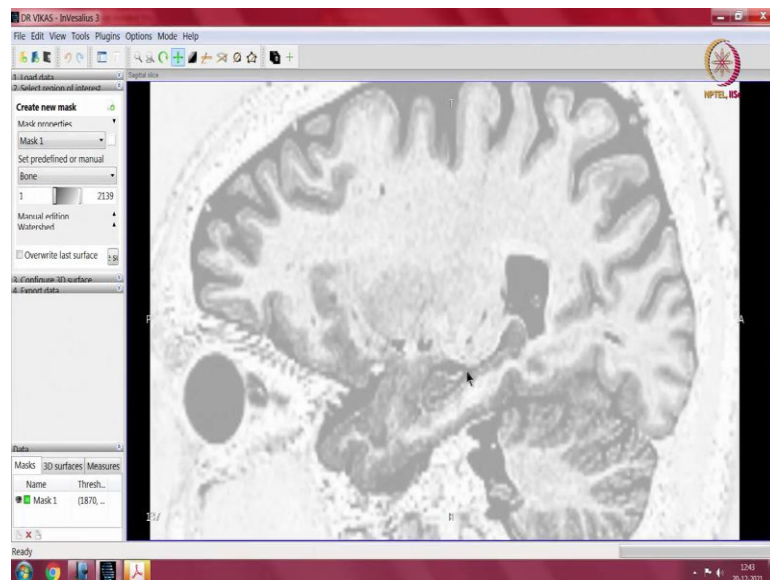
So, the hippocampus curves around the thalamus and forms the phonics.

(Refer Slide Time: 45:53)



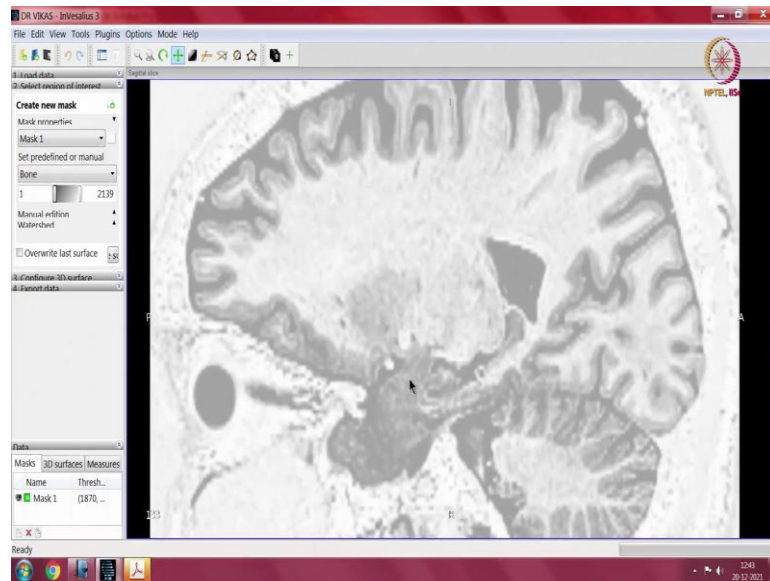
So, this is the phonics, cannot make out very clearly where it is curving around, but then you go laterally you would find that it is going into the hippocampus.

(Refer Slide Time: 46:00)



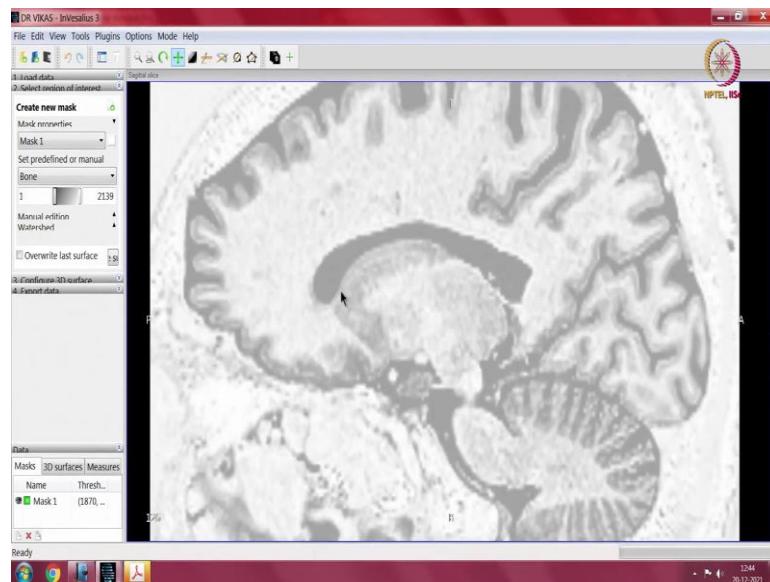
Now, just above the hippocampus is the other structure which I wanted to highlight.

(Refer Slide Time: 46:06)



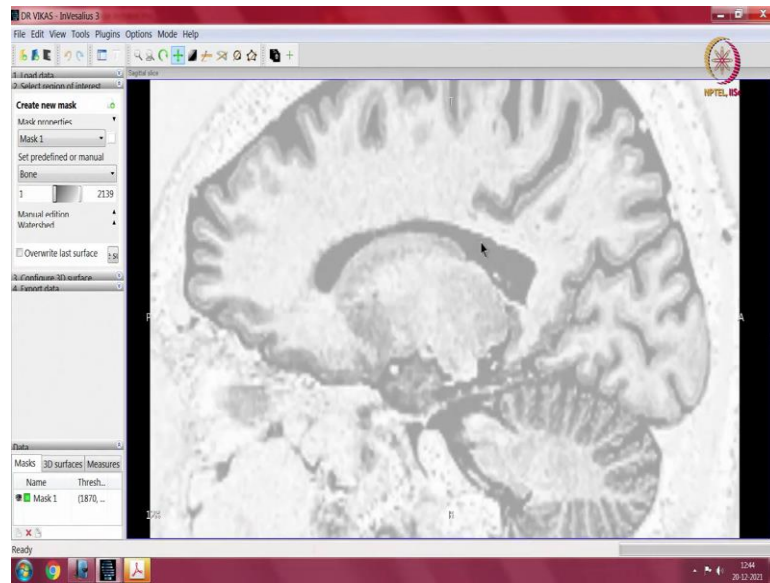
So, if this is the hippocampus sectional anatomy, please remember this is sectional anatomy this gray structure over here is the amygdale. And the amygdala is closely related to the lentiform nucleus over here. So, when we go back into the ventricle this is the frontal horn.

(Refer Slide Time: 46:30)



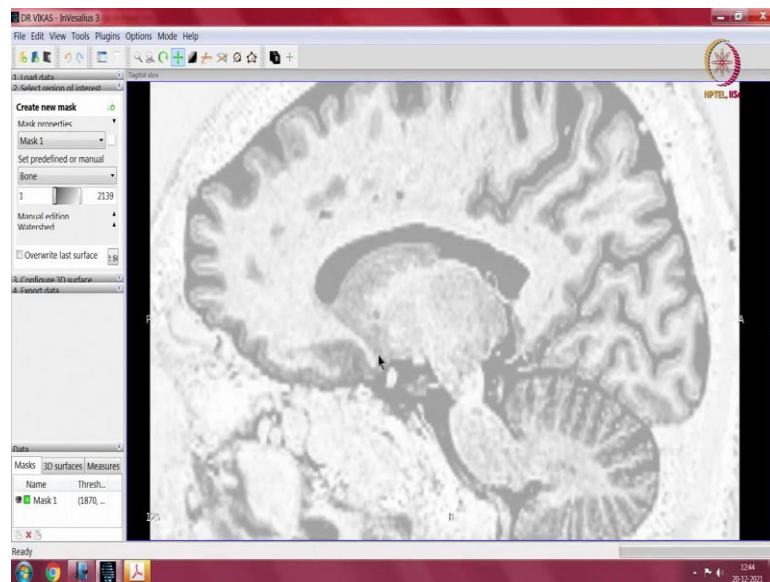
There is another gray structure over here which is here seen over here. So, this gray structure is the caudate nucleus projecting into the ventricle.

(Refer Slide Time: 46:42)



You can see that it is distinctly projecting into the ventricle this thing, this thing, this thing, this thing is the caudate nucleus.

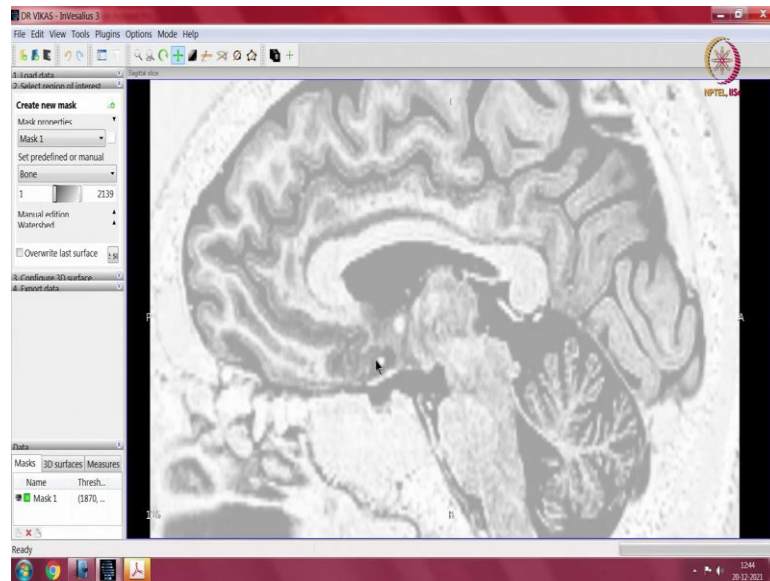
(Refer Slide Time: 46:51)



So, head of the caudate nucleus is just about somewhere here.

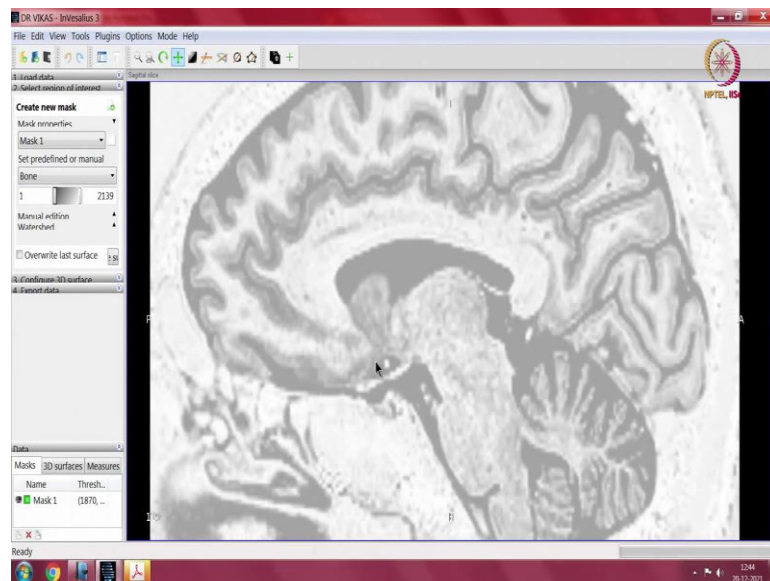


(Refer Slide Time: 46:55)



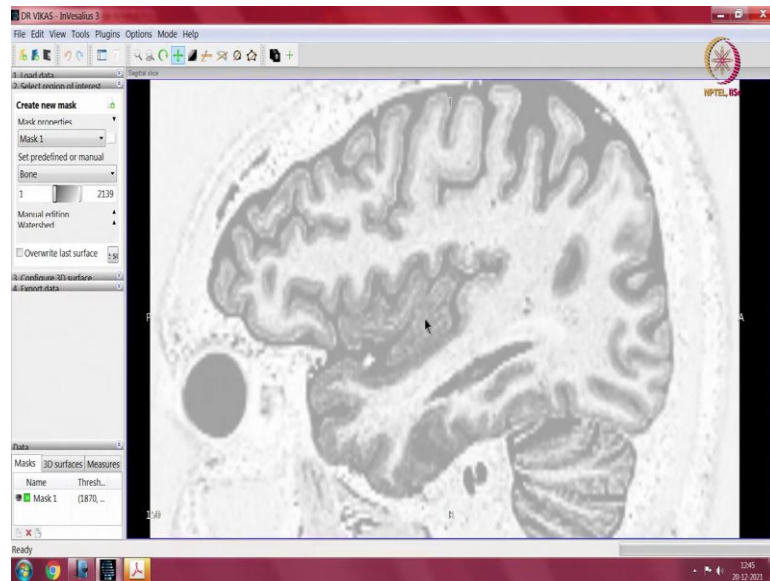
And that is how it gets. See again you cannot make out distances here.

(Refer Slide Time: 46:57)



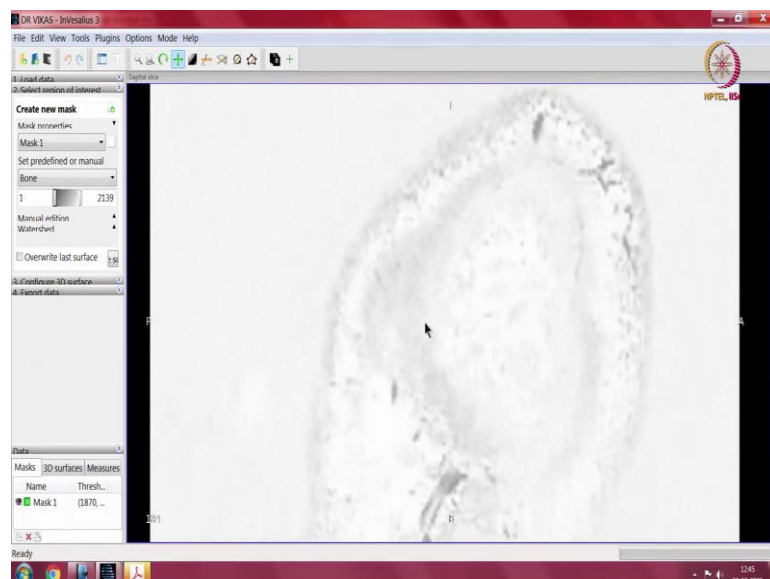
Because they are in different sagittal planes. So, that is how the; that is how the marking is.

(Refer Slide Time: 47:10)



And we need to identify insula. So, insula is this. So, you can see white matter all around. So, it is indicating deep within the surface, within the brain matter and suddenly you see gray matter over here. So, gray matter with cortex, sulci and subarachnoid space. So, this is subarachnoid space, subarachnoid space, subarachnoid space and that is the insula.

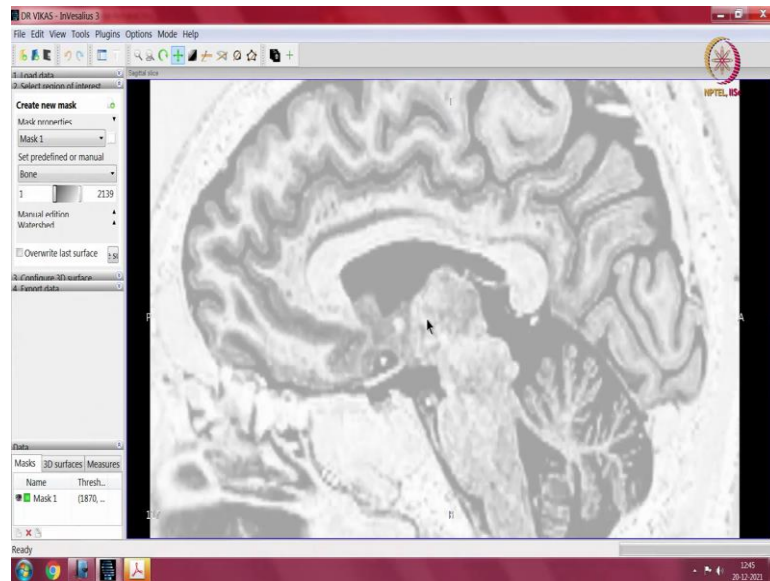
(Refer Slide Time: 47:35)



So, that is about how you interpret structures these are very broad structural descriptions.

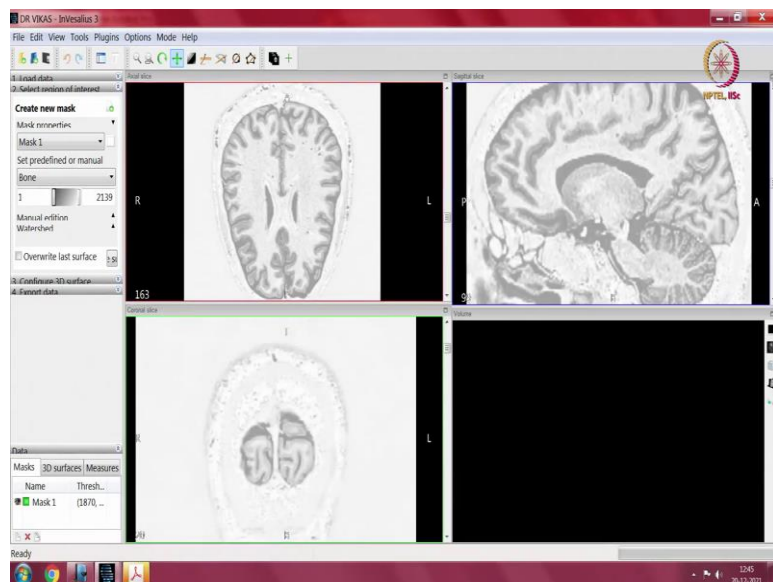


(Refer Slide Time: 47:47)



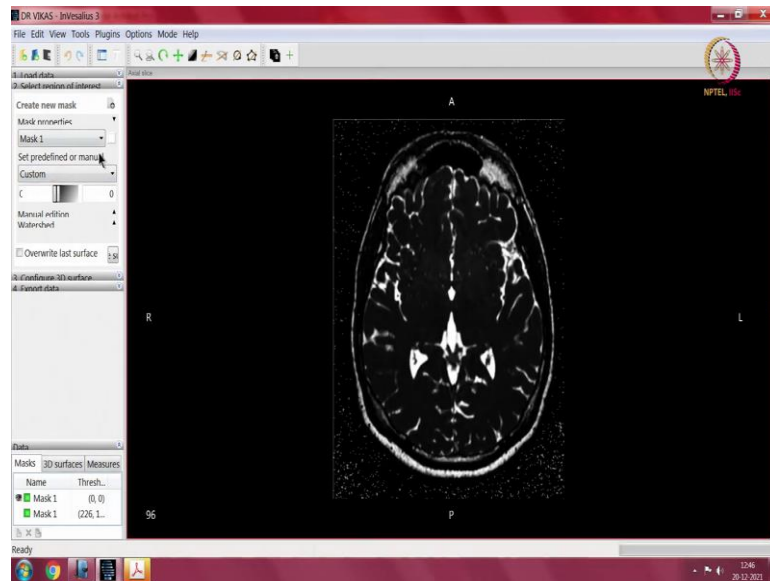
But it is to give you an idea of what is situated where ok. And how these things look like? I tried showing it to you in 3D. Now I showed it in axial I will try showing it in another sequence.

(Refer Slide Time: 48:00)



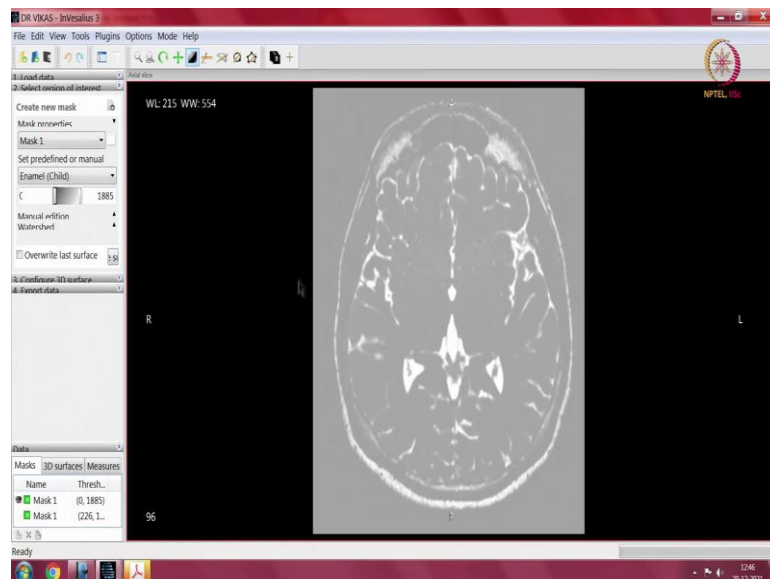
So, this is a T 1 sequence I will be showing you.

(Refer Slide Time: 48:45)



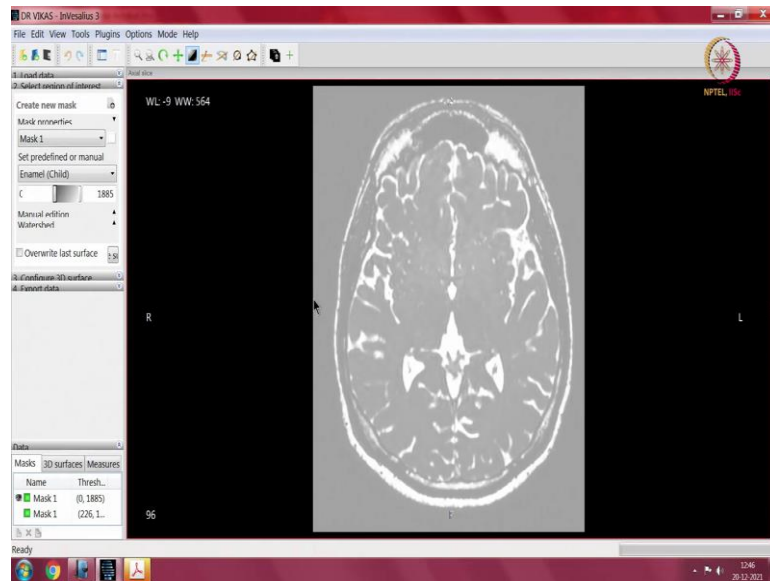
So, this is something called as a CISS image.

(Refer Slide Time: 49:52)



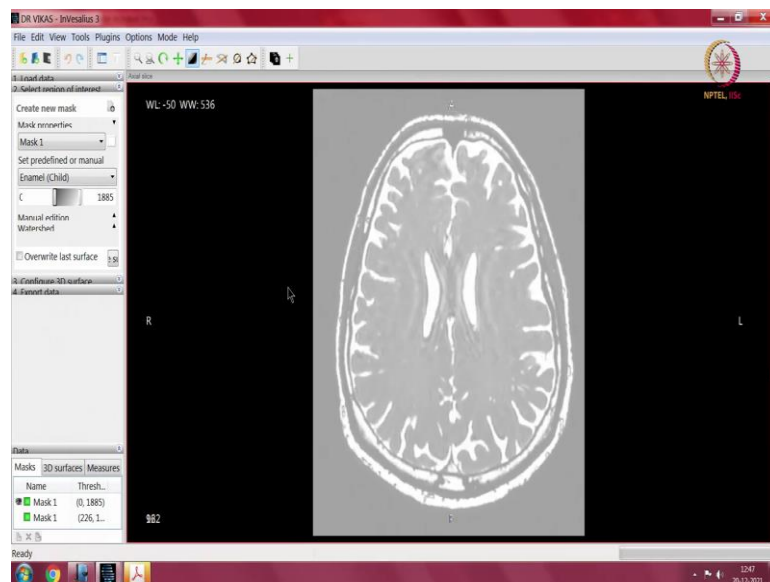
So, CISS image again its a gray scale image. What is best in this image is that you can make out structures which are outside and inside of the brain ok.

(Refer Slide Time: 49:05)



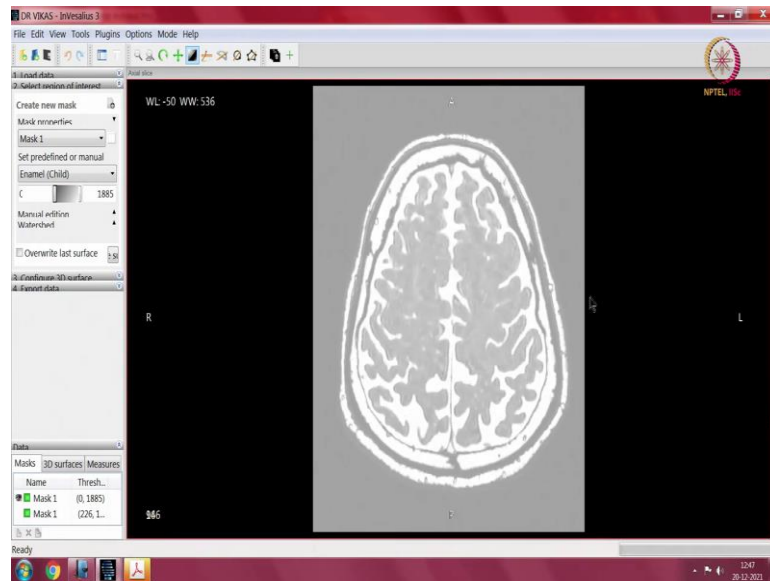
So, that is the idea. So, if you recollect from my earlier discussion, I spoke a lot about the structural anatomy without delving into the gyri, sulci, nothing of that discussion was there. So, that is being described over here.

(Refer Slide Time: 49:28)



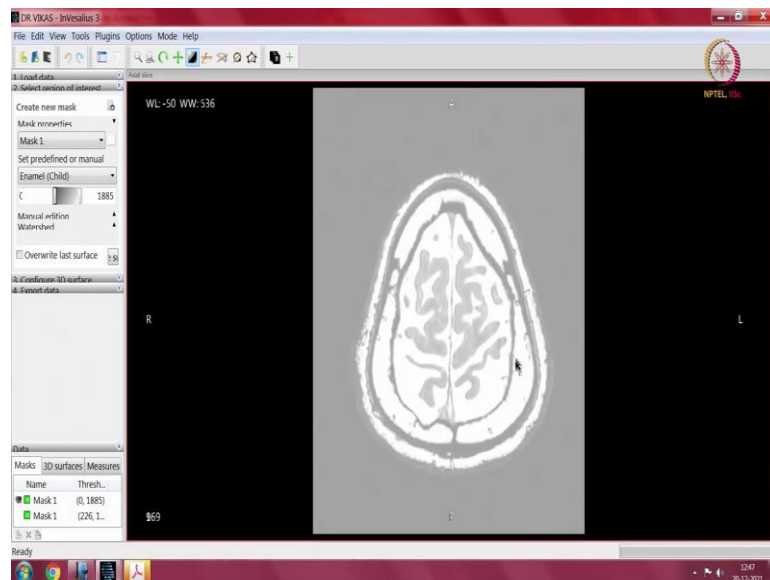
And we will see how best to make use of this image in understanding about the gyri and sulci.

(Refer Slide Time: 49:36)



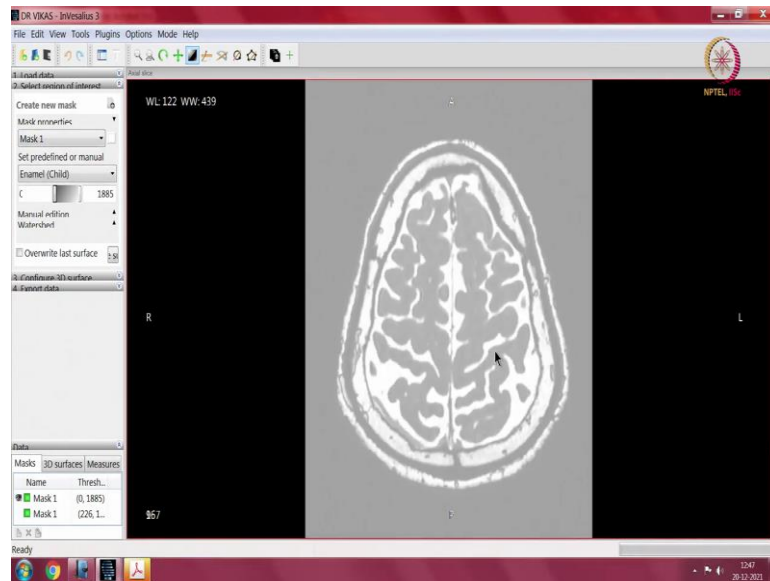
So, gyri and sulci are now very obvious. You can see so many gyri over here and each depression is called as the sulcus and there are so many sulci around here.

(Refer Slide Time: 49:46)



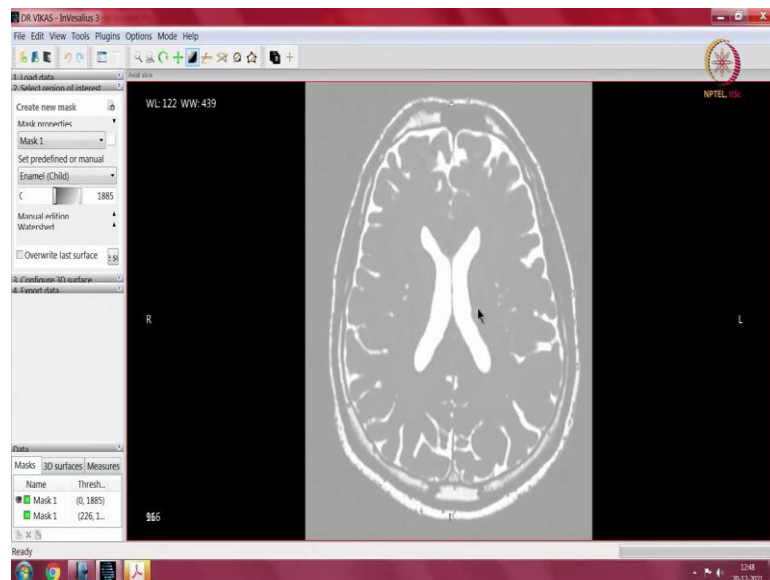
So, how do we make sense of an image like this and try to map our 3D knowledge which we acquired earlier and put it on to this. So, for that reason we will start with notions which we had already solidified, concrete ideas and we take up that.

(Refer Slide Time: 50:03)



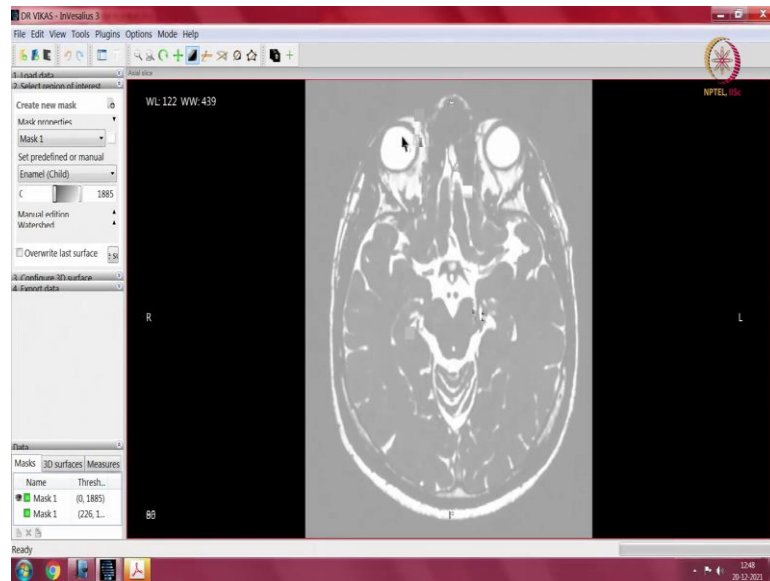
So, this is axial section. So, when I say axial section there is left, right, anterior and posterior. How do we make out anterior and posterior?

(Refer Slide Time: 50:18)



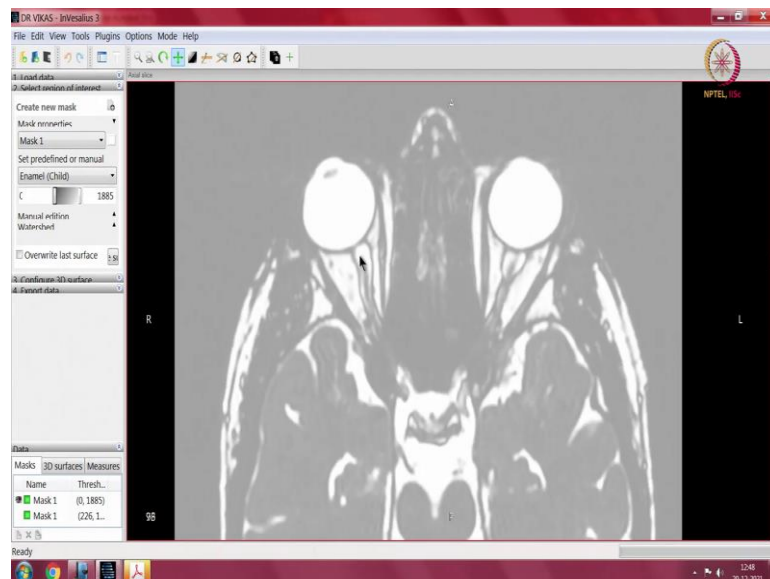
We scroll through that confirm our anterior part has eyes.

(Refer Slide Time: 50:24)



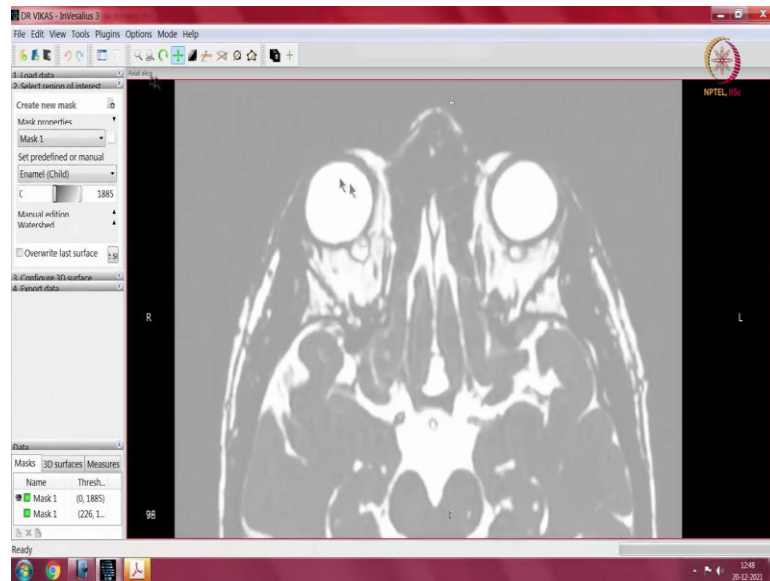
So, these are eyes; obviously and you can distinctly make out the optic nerves.

(Refer Slide Time: 50:31)



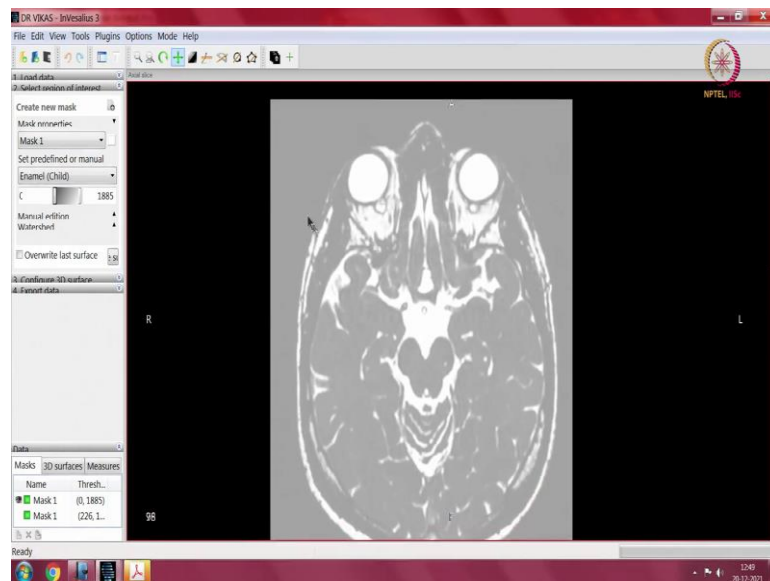
So, you can see the optic nerve over here. So, this is the optic nerve. And you can see it is pretty lazy, lazy as in loose. And that is because to accommodate for the rotations of the eyeball within the socket, you know the nerve should not get stretched, it does not get stretched when you look towards one direction. that is the optic nerve, this is the eye ball, this black thing is actually the lens, this is the nose.

(Refer Slide Time: 51:04)



So, orientation done we go back to our primary description axial section.

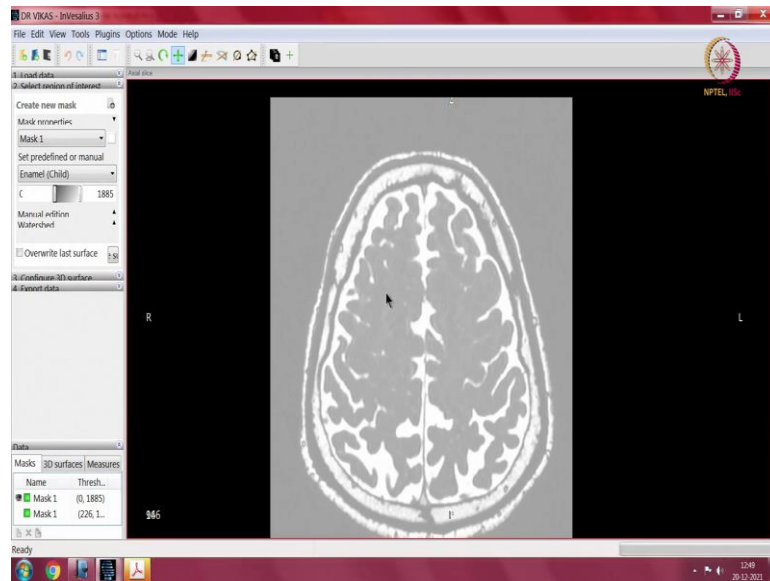
(Refer Slide Time: 51:15)



So, we can scroll above and below to find out. So, I am going above how do I know that I am going above?

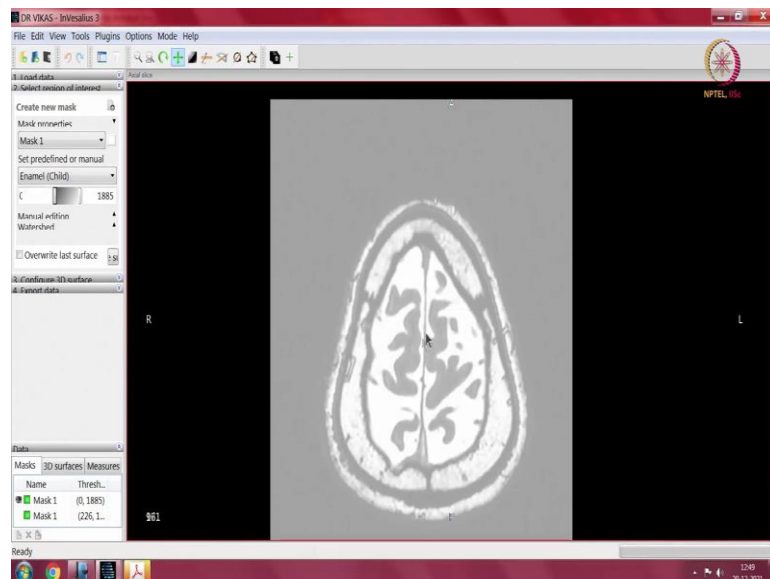


(Refer Slide Time: 51:27)



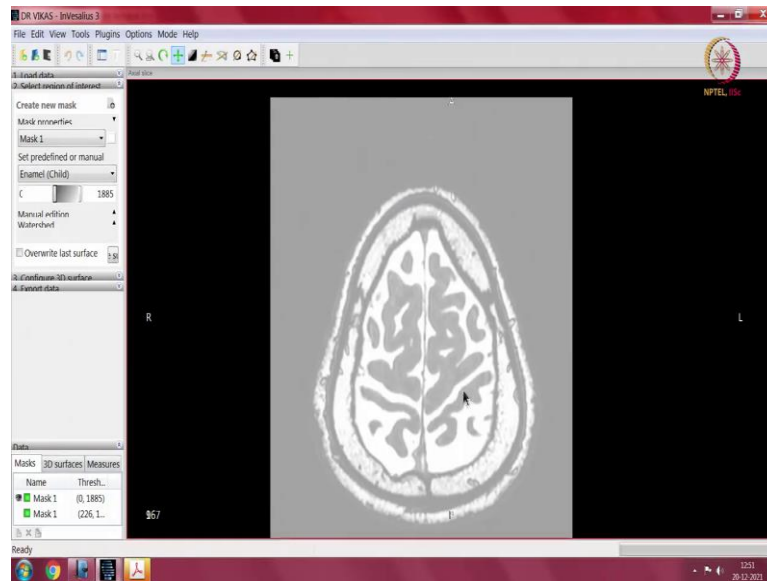
Because I am still seeing cerebrum and I am not seeing brainstem.

(Refer Slide Time: 51:31)



So, if I am going down, I should be seeing brainstem. So, as supposed to the T 1 you can distinctly see this why a gray line over here which is splitting it into two halves. And this grey line is the falx cerebri.

(Refer Slide Time: 51:48)



So, falx cerebri now that we have identified the falx cerebri and said that this is the left cerebral hemisphere right cerebral hemisphere and we have acknowledged the presence of gyri and sulci, we need to look at the midline. So, midline has all this swelling. So, gyri one, then there is a sulci here and then there is a sulcus here and then suddenly we dip into here and then find that this sulcus is going all the way through up to the lateral part. So, that is a key differentiating discovery and its important because by that we have identified the central sulcus.

Now, I told you that it may not be easy in everybody to identify all these structures. So, we need multiple markers of the central sulcus and that is the purpose of showcasing this image. Now what are the other markers of the central sulcus? The central sulcus is important reiterating stuff which I have already highlighted.

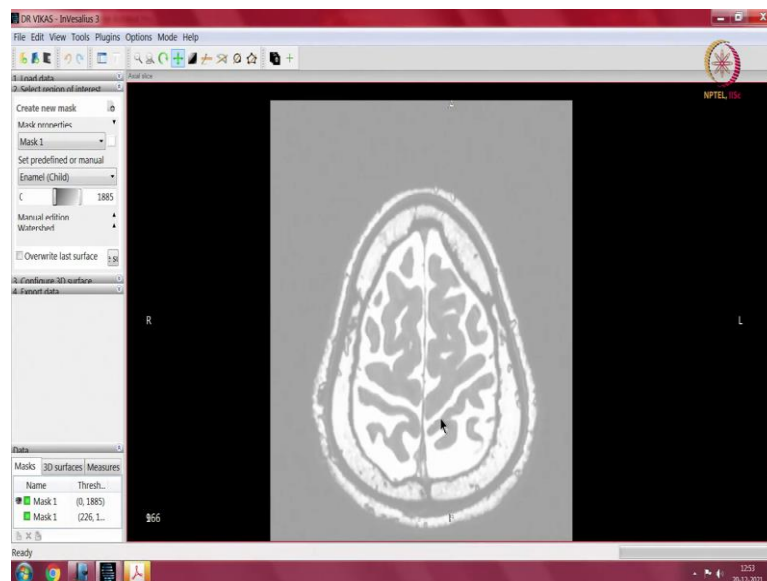
The central sulcus divides the brain into an anterior active part which is the motor part of the brain versus a posterior part which is the sensing part of the brain. They are not strictly rigid in terms of acting part, because acting as in functional; function as in implementing part, implementing includes judgment decisions thought everything is an action.

And so, that is what is happening in the anterior part of the brain. So, going back to the image, this is the central sulcus. So, what comes anterior to it, what is the gyrus anterior to it? You can see it is thick, this gyrus is thick when compared to this gyrus over here.

Same thing on the opposite side, thick gyrus, thin gyrus. So, the thinner gyrus is the sensory cortex, thicker gyrus is the motor cortex number 2. So, reiterating the sulcus which goes from the center all yes.

So, that is the central sulcus, thicker motor cortex and the thinner sensory cortex. You have to come up to actually find out where the sulcus starts from.

(Refer Slide Time: 55:54)



So, if you go down deeper you would find that the same sulcus is only on this side and it is not communicating over here. So, that is a key step. So, we will break here and then continue along with this. So, we have identified midline and how to identify structures on the surface of the brain just using brain imaging to find out the what stuff I taught you in 3D on the 2D ok.